




Dry Eye Diagnosis



Clinical Atlas

Authors

Natasha Pahuja, Luca Vigo, Shri Ganesh, Sergio Solarino,
Franco Spedale, Francesco Blasetti, Eros Radrizzani



Index

INTRODUCTION	pag. 4
STANDARD PROCEDURE	pag. 5
DRY EYES DISEASE	pag. 10
CAUSES / REMEDIES	pag. 11
AUTHORS	pag. 12
CLINICAL CASES	pag. 15
CASE 1 Ocular mucous membrane pemphigoid	pag. 16
CASE 2 Blepharitis	pag. 20
CASE 3 Meibomian gland dysfunction (MGD)	pag. 24
CASE 4 Evaporative Dry Eye	pag. 28
CASE 5 Hypo lacrimation due to aqueous deficit	pag. 30
CASE 6 Evaporative Dry Eye with poor lipid component	pag. 32
CASE 7 Meibomian Glands Dysfunction	pag. 34
CASE 8 Dry Eye due to excessive evaporation	pag. 36
CASE 9 Dry Eye with altered lipid secretion	pag. 38
CASE 10 Evaporative Dry Eyes	pag. 40
CASE 11 Post Lasik Severe Dry Eye	pag. 44
CASE 12 Dry Eye	pag. 48
CASE 13 Post Presbyopic Lasik	pag. 52
CASE 14 Evaporative Dry Eye	pag. 56
CASE 15 Severe Dry Eye	pag. 60
CASE 16 Phacoemulsification follow-up	pag. 64
CASE 17 Evaporative Dry Eye	pag. 66
CASE 18 Meibomian gland dysfunction (MGD)	pag. 68
CASE 19 Post Lasik Dry Eye	pag. 72
CASE 20 Evaporative Dry Eye with conjunctival chalasis	pag. 76
SCIENTIFIC ARTICLE BY CORNEA	pag. 78
BIBLIOGRAPHY	pag. 83
ACKNOWLEDGMENTS	pag. 84

INTRODUCTION

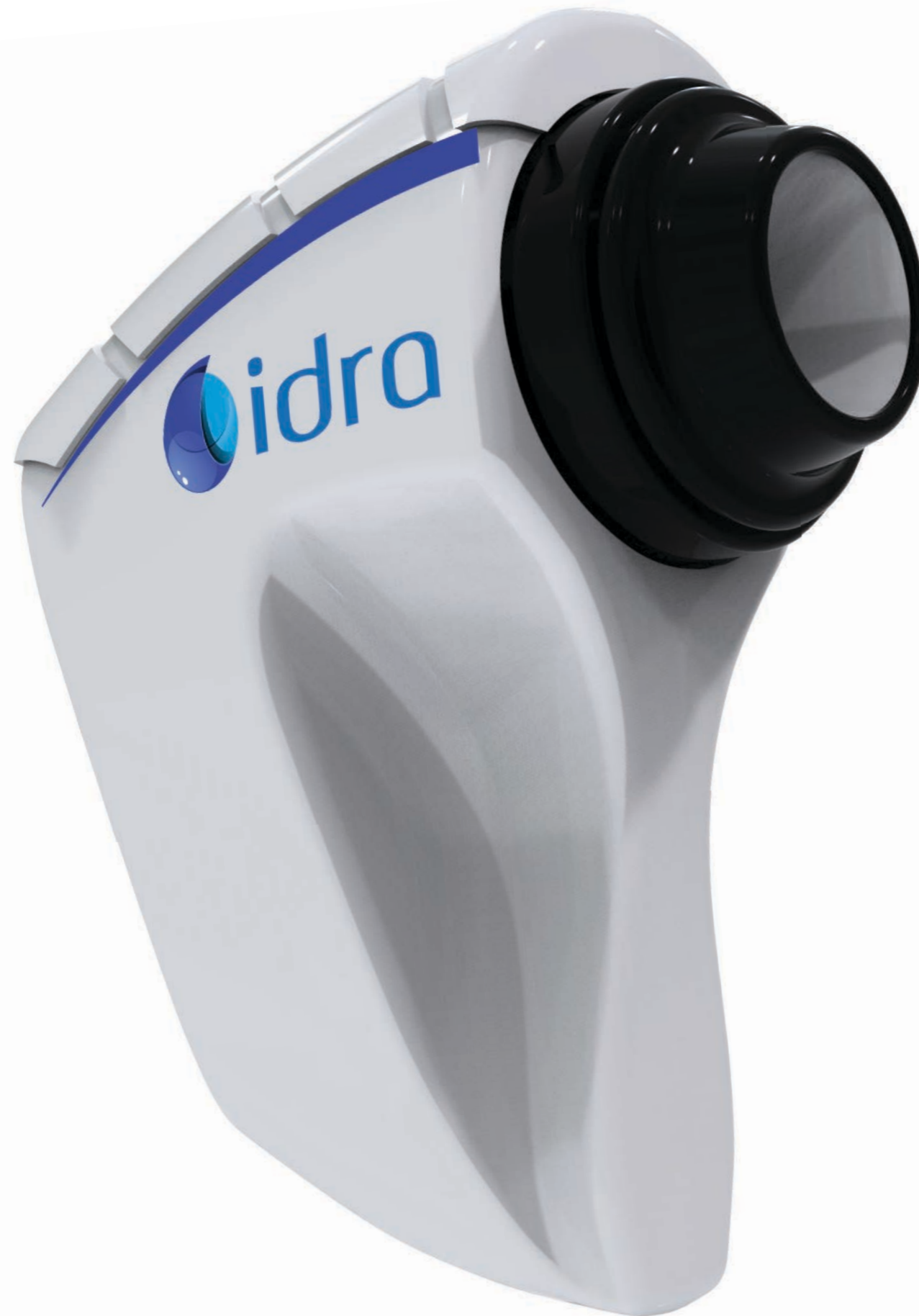Our innovative and experienced team of scientists, physicians, researchers and business leaders have dedicated much of their lives to advancing treatments for ocular diseases.

The instrument IDRA is fitted in the slit lamp tonometer's hole, it is designed to make all the related tear film tests, from the quality of each tear layer to the analysis of Meibomian glands, as well as various measurements and classifications according to international grading scales.

The device's purpose is to analyse the diagnostic performance of an ocular surface workup based on automated non-invasive measurements in the diagnosis of meibomian gland dysfunction (MGD).

Dry Eye Disease (DED) is a multifactorial pathological condition that involves many ocular surface alterations caused by lacrimal dysfunction. The resulting symptoms are ocular surface inflammation, visual disturbances, subjective annoyance and general discomfort. In cases where the pathological condition is more serious, the daily life of the person is influenced, and the simplest habits become complicated.

For this reason, a number of well-known DED specialists started to use IDRA to support their clinical diagnosis and they have kindly shared their case studies for you in this Atlas.



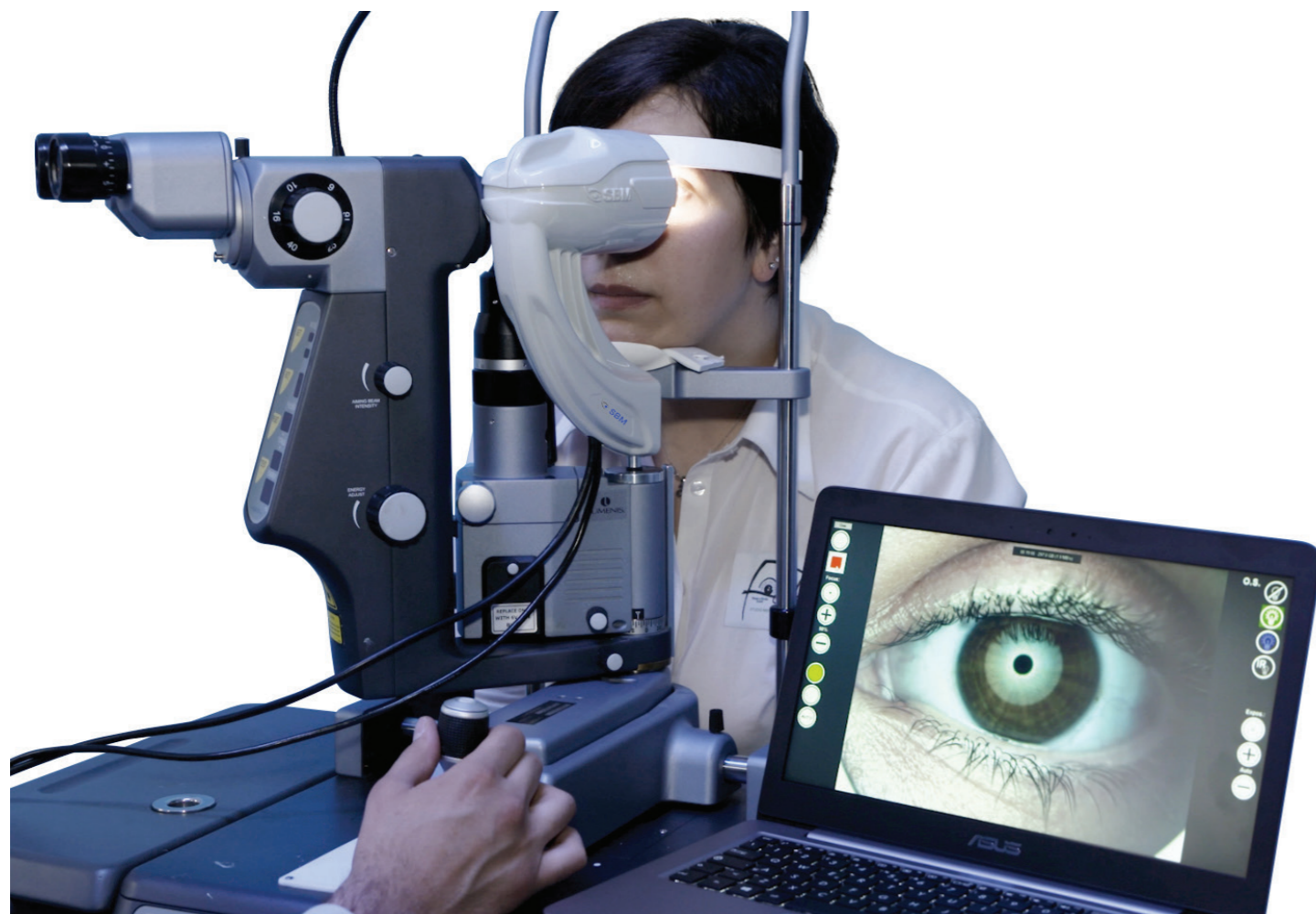STANDARD PROCEDURE

It is crucial to check the quality and quantity of tear film.

After Osmolarity test and the subjective questionnaire, it is necessary to follow a standard clinical procedure.

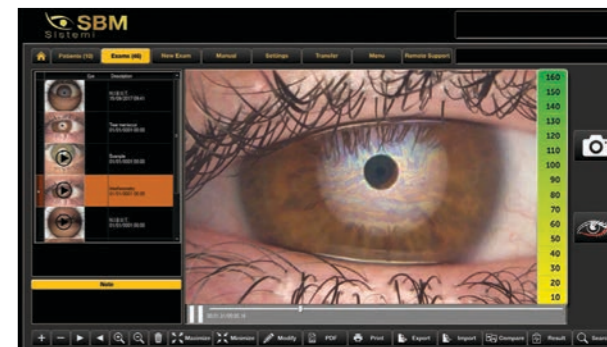
The quality of tear film may be effectively detected doing the following exams:

1. Interferometry
2. Tear meniscus
3. NIBUT
4. Meibography
5. Blepharitis and Demodex
6. Conjunctiva and cornea's status and Staining



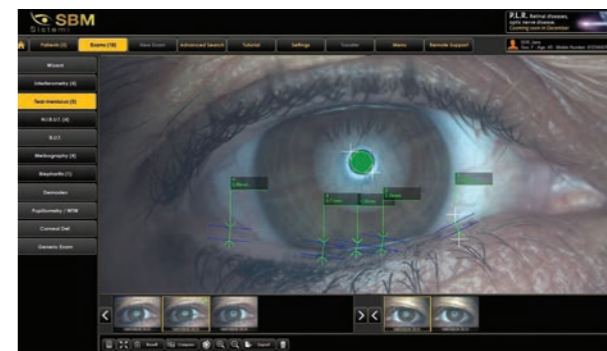
1. Interferometry

Interferometry test studies lipid layer thickness through the international grading scale. Depending on the provided pattern, the lipid layer can be classified between 15 nm and 160 nm.



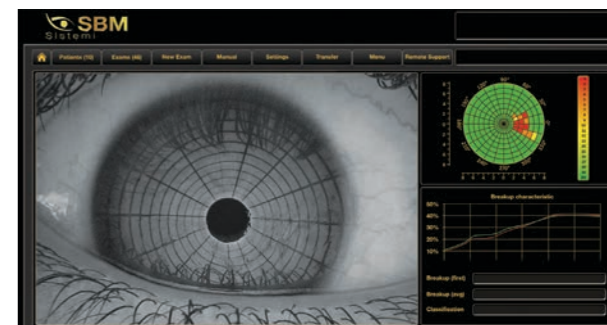
2. Tear meniscus

Tear meniscus concerns the amount of water in tear film in millimetres, in a non-invasive way and without considering reflex tears. With IDRA, it is possible to observe its stability and position on the eyelid through the acquisition of a photo.



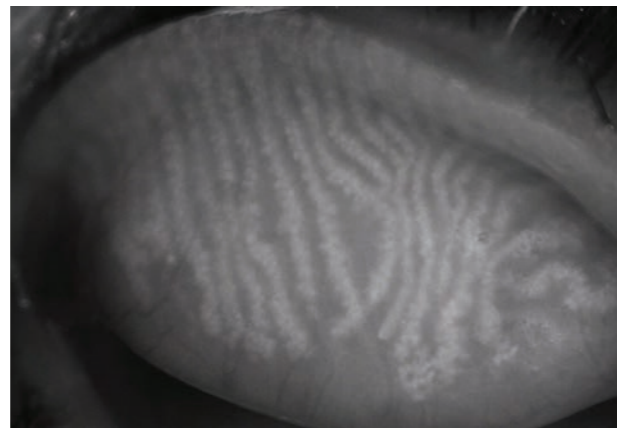
3. NIBUT

NIBUT allows to evaluate stability of the mucinic layer and regularity of the tear film using provided grids, and it is completely automatic. The automatic non-invasive break up time is the measurement, in seconds, of the time between the last complete blink and the appearance of the first discontinuity on the tear film.



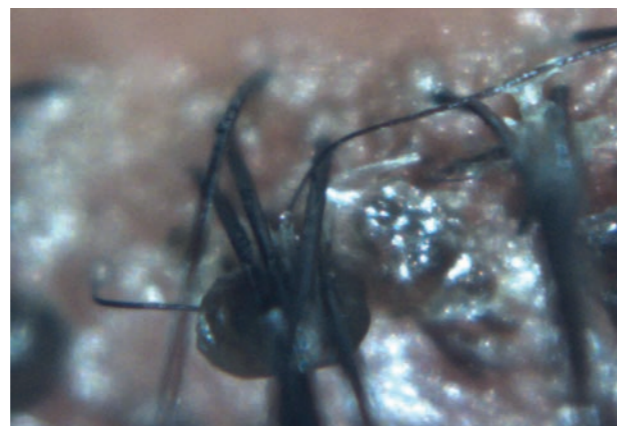4. Meibography

Meibography is made with Near-Infrared light. The photo of upper or lower palpebral conjunctiva is elaborated automatically by IDRA, which gives the percentage of loss area of the Meibomian Glands.



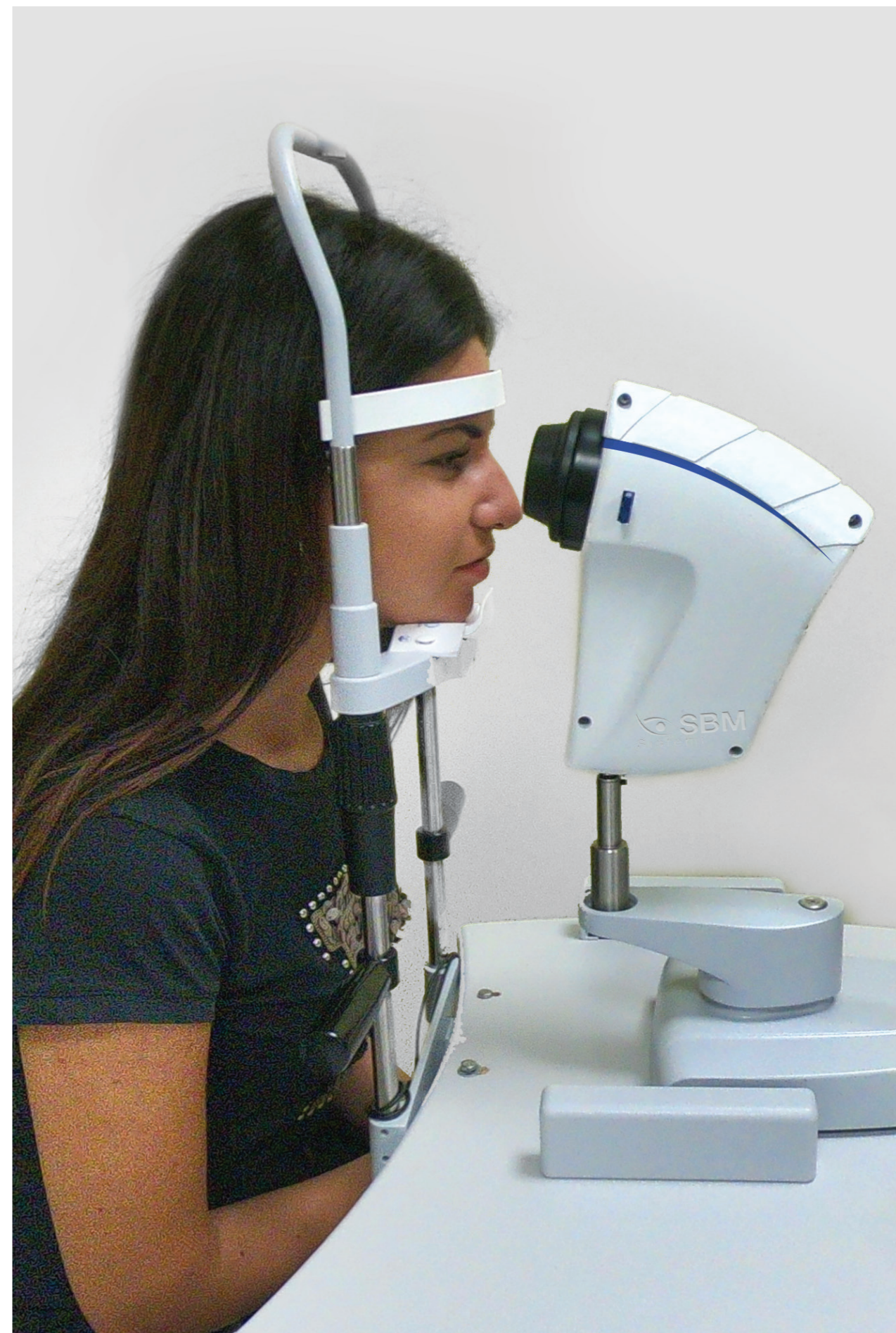
5. Blepharitis and Demodex

With magnification tools it is possible to verify the status of inflammation related to eyelids.



6. Conjunctiva and cornea's status and Staining

By using the yellow filter of IDRA and fluorescein on patient's eye, the device allows you to check conjunctival and corneal staining and to classify the condition through the relevant grading scales.



DRY EYES DISEASE

The accurate diagnosis and classification of dry eye are complicated by the heterogeneous nature of the disease and the variability of signs and symptoms. Various diagnostic assessments have been proposed to qualitatively and quantitatively characterize the entire ocular surface system. However, to date, no universally accepted diagnostic workup for the diagnosis of MGD has been established.

Several tests used routinely in daily practice require direct contact with the eye and/or the use of eye drops. The resulting alteration of the tear film volume and composition may not only influence the measured variable itself but also have disruptive effects on the results of subsequent tests. In addition, some tests require the clinician's judgment to reach a score and, therefore, are open to significant observer bias. Furthermore, measurements obtained using traditional tests are often affected by low values of repeatability and reproducibility. Recently, new automated non-invasive quantitative tests have been developed to overcome these drawbacks. They include, among others, tear film interferometry, noncontact meibography, and tear osmolarity.

In particular, interferometry is a technique that studies the surface reflection pattern and dynamics of the lipid layer of the tear film, thus allowing the measurement of the tear film stability and the thickness of the lipid layer. The measurement of BUT with a non-invasive technique eliminates the disturbance on the tear film caused by instillation of fluorescein dye. Meibography allows in vivo observation of the meibomian gland morphology; the gland structural changes may be graded with different scoring systems. In addition, new digital software allows automated calculation of the total meibomian gland area in the lower and upper eyelids.

Tear film osmolarity has been reported as the single best metric to diagnose and grade severity of dry eye. Early in the evolution of this technique authors questioned its clinical utility because of the high variability of measurements and the lack of correlation with dry eye signs and symptoms, however subsequent publications have shown that the variability is a part of the disease and that Osmolarity done correctly has the highest single sensitivity and specificity of any single DED metric.

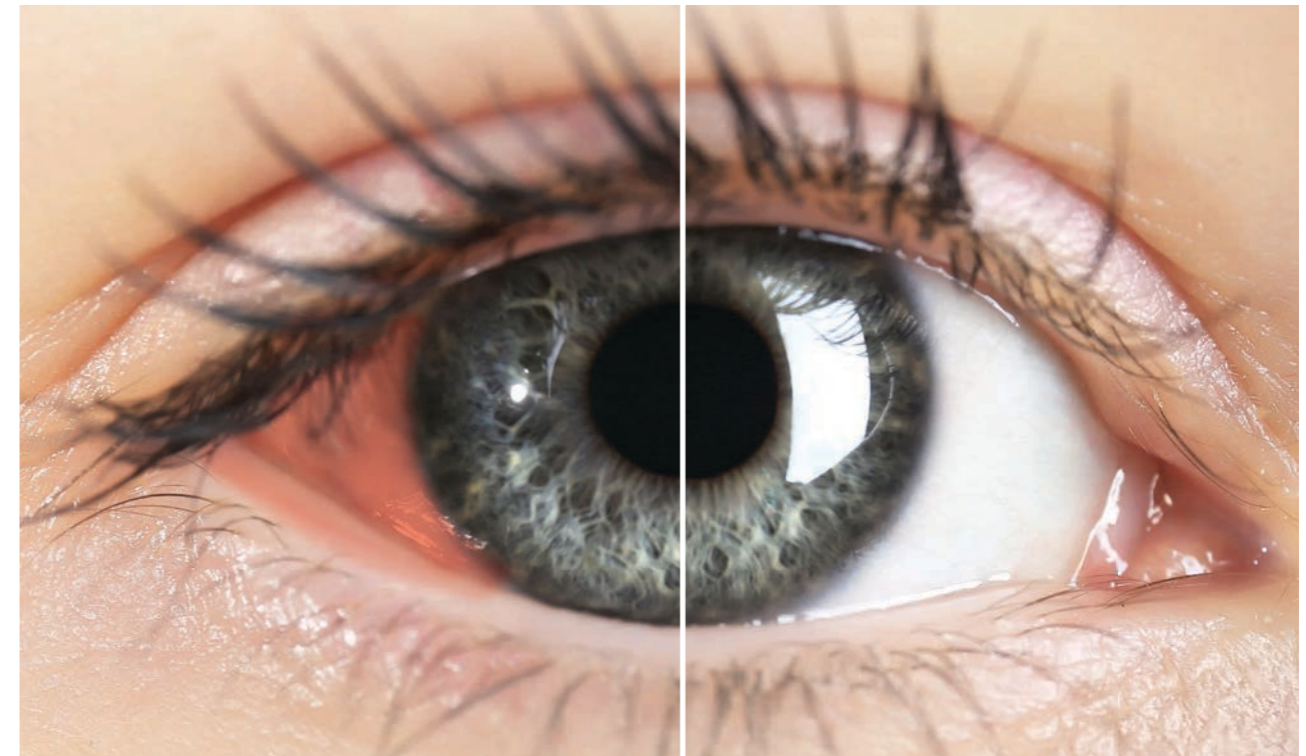
HOW IS DRY EYE DIAGNOSED?

OCULAR SURFACE WORKUP WITH AUTOMATED NON-INVASIVE MEASUREMENTS FOR THE DIAGNOSIS OF MEIBOMIAN GLAND DYSFUNCTION

Dry Eyes can be diagnosed through a complete eye examination.

Testing, with emphasis on the evaluation of the quantity and quality of tears produced by the ocular glands, may include:

- Patient history to determine the patient's symptoms and to note any general health problems, medications or environmental factors that may be contributing to the dry eye problem.
- External examination of the eye, including lid structure and blink dynamics.
- Evaluation of the eyelids and cornea using bright light and magnification.
- Measurement of the quantity and quality of tears for any abnormalities. Special dyes may be put in the eyes to better observe tear flow and to highlight any changes to the outer surface of the eye caused by insufficient tears.



CAUSES

- The natural aging process, especially menopause
- Diseases that affect your ability to make tears, like Sjogren's syndrome, rheumatoid arthritis, and collagen vascular diseases
- Conjunctivitis
- Environmental conditions. Exposure to smoke, wind and dry climates can increase tear evaporation resulting in dry eye symptoms. Failure to blink regularly
- Problems that don't allow your eyelids to close in the right way
- Cataract and corneal surgeries may increase dry eye symptoms
- Treatment with Medications including antihistamines, decongestants, blood pressure medications and antidepressants, can reduce tear production
- Other factors. Long-term use of contact lenses can be a factor in the development of dry eyes
- Refractive eye surgeries, such as LASIK, can decrease tear production and contribute to dry eyes.

REMEDIES

- Treatment with Artificial tears
- Steroid Eye drops
- Restasis
- Xiidra
- Lacrisert
- Punctal plugs
- Intense Pulsed Light therapy has been used with positive results if there are oil gland problems
- Use of a cool mist humidifier to add moisture to the air
- Drink water throughout the day to stay hydrated
- Warming of the Meibomian Glands
- Specific diets.

AUTHORS



DR. Natasha Pahuja

Is a Cornea & Refractive Surgeon at Natasha Eye Care & Research Centre, Pune India. Dr Natasha Pahuja is a PhD scholar at the Maastricht University Netherlands. She is a clinical & research scientist at the GROW Research laboratories. Her research is based on molecular biology to understand pathways driving diseases. Dr Natasha Pahuja has many publications to her credit and also serves as a member of editorial board for many international peer reviewed journals. Dr Natasha Pahuja won the extremely acclaimed Colonel Rangachari award at the annual meeting of the AIOS (All India Ophthalmological Society Conference) for the best paper of the country for her discovery in pathways of Keratoconus & devising a novel treatment for this intriguing disease. She also won the E.T SELVAM AWARD BEST POSTER award for her research on Refractive surgery and LASIK. This is the first time in history of 75 years of All India Ophthalmological society that two out of three prestigious awards have been given to the same doctor.



DR. Luca Vigo

Is the Coordinator for general ophthalmology. He is mainly engaged in refractive surgery and cataract surgery. 1999-2000 Assistant in ophthalmology at the Department of Ophthalmology and Vision Sciences, San Raffaele Hospital in Milan (Dir. Prof. Rosario Brancato) 2000-today Associated at Carones Ophthlmo-Surgical Center in Milan. Classical maturity achieved in 1989 in Milan. Graduation in Medicine and Surgery at the University of Milan in 1995 (110/110 with honors). Specialization in Ophthalmology at the University of Milan in 1999 (70/70 with honors). 1994- Fellowship in refractive surgery at the Department of Ophthalmology at University of California in Los Angeles (UCLA) of the Jules Stein Institute (Dir. Robert Maloney, MD).



DR. Sri Ganesh

Chairman & Managing Director, Nethradhama Hospitals Pvt Ltd, Bangalore, India, Medical Director, Nethradhama Super Speciality Eye hospital. Bangalore, India, Managing Trustee: Shraddha Eye Care Trust, Bangalore, India, Memberships: Karnataka Medical Council, India. (KMC) KMC-29854, Indian Medical Council. (IMC), All India Ophthalmological Society. (AIOS) membership no: 05250, Karnataka Ophthalmological Society. (KSO) – 262, Bombay Ophthalmological Society (BOS) Bombay Ophthalmologists Association (BOA), American Academy of Ophthalmology (AAO), American Society for Cataract and Refractive Surgery (ASCRS), European Society for Cataract and Refractive Surgery (ESCRS), (APACRS), Bangalore Ophthalmic Society (BOS), Keracon IIIC Membership International Society of Refractive Surgery (ISRS).



DR. Sergio M. Solarino

CEO & Founder and managing director of Centro Vista in Cagliari Area, Italy. Mainly focused on anterior segment surgery, like cataract and refractive surgery, he performed up to now more than 50.000 procedures and counting. He is also Head Consultant in S. Antonio private clinic, Tommasini private hospital and Policlinico città di Quartu. Received steadily in recent years, the invitation to participate in the live surgery sessions of major Italian and international congresses (SOI - OSN - AICCER - ESCRS). In Centro Vista he recently founded and coordinates with his medical staff, the first "Sardinian Dry Eye Center" for diagnosis and treatment of Dry Eye.



DR. Franco Spedale

Graduated in Medicine and Surgery at the University of Brescia with full marks and specialized (1999) in Clinical Ophthalmology at the Faculty of Medicine and Surgery of Brescia with the maximum result. In 2000 he began his professional activity. Since 2006 he has opened and directs the U.O. of Ophthalmology in Chiari. It has more than 1,400 operations per year and over 25,000 diagnostic and therapeutic services. Member of several authoritative scientific societies, he has been a speaker in numerous National and International congresses. He has performed numerous observational studies with pharmaceutical companies to test new products. It possesses a surgical technique for the traditional intervention of cataract which allows, unique in its kind, to use less than 1 second of ultrasound. He is among the first Italian surgeons to have an experience with the LASER surgery of the cataract.



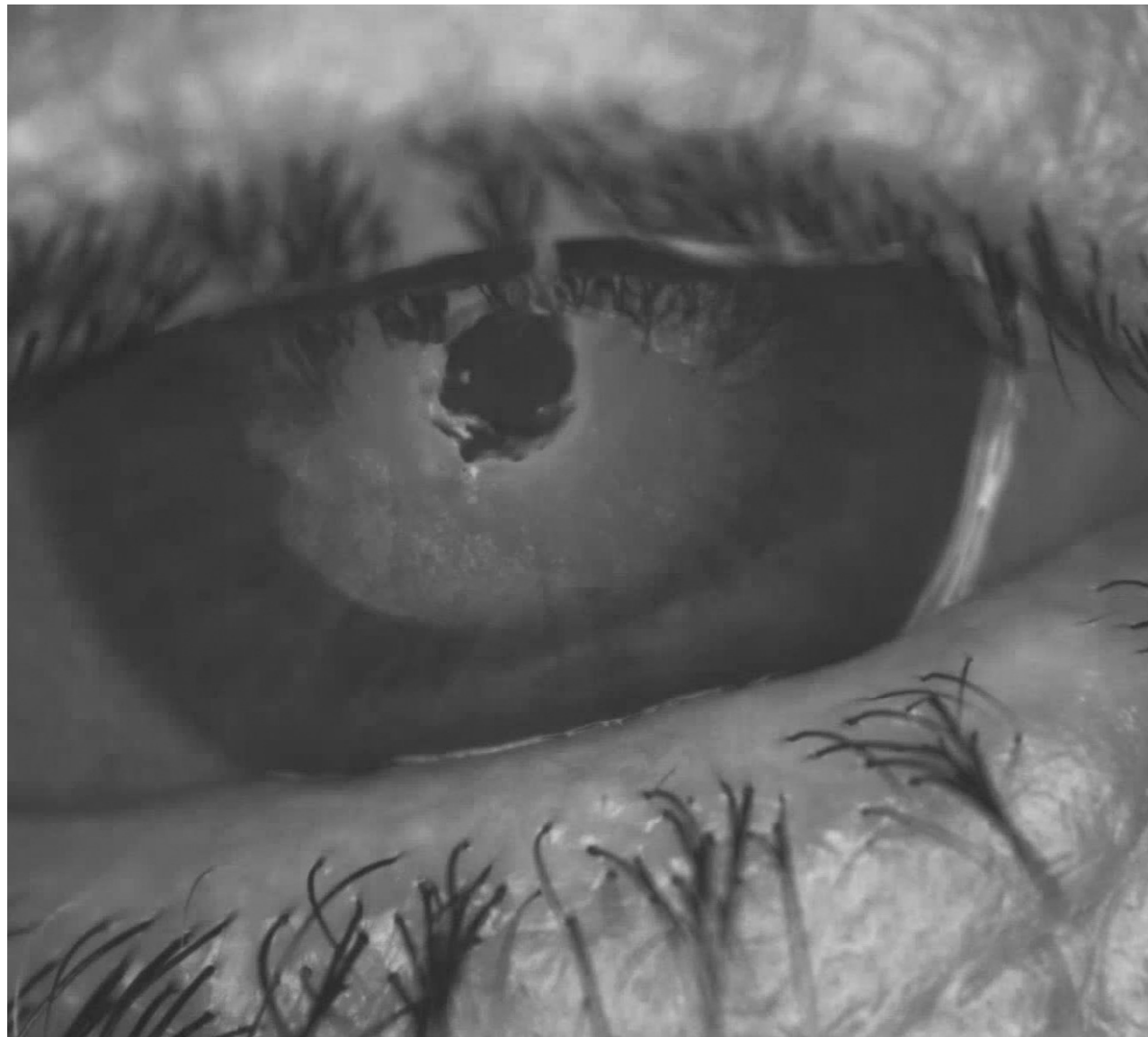DR. Eros Radrizzani

1984: Degree in Medicine and Surgery at the University of Milan and qualification for the practice of the University of Milan. 1988: Specialization in Ophthalmology with honors at the University of Milan. He started practicing since 1987, becoming Manager of the first level and Medical Advisor in the eye discipline at H.S.L. Mandic of Merate. Instructed to teach Ophthalmology at the nursing school Professional Hospital San Carlo Borromeo. From 2002 to 2018 participates in training courses of E.C.M for a total of 758.2 credits and scientific publications and congresses. Co-responsible for the integrated diagnostic and treatment of Ocular Surface pathology at the "Clinica Castelli" Bergamo Ophthalmology clinic, and enrolled in the "Lacrime Nazionale" Project.



The only complete tool for assessing
the ocular surface

CLINICAL CASES



Case 1 – Ocular mucous membrane pemphigoid

Dr. Natasha Pahuja

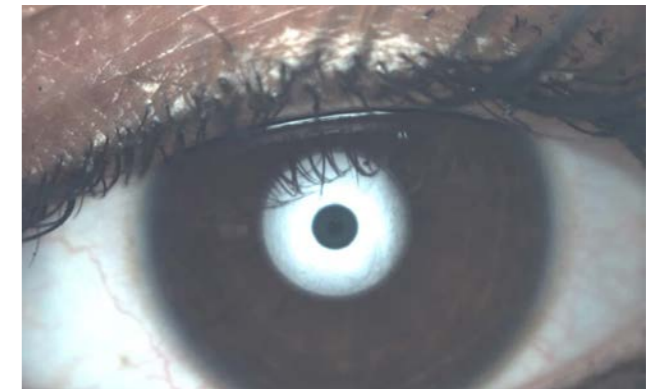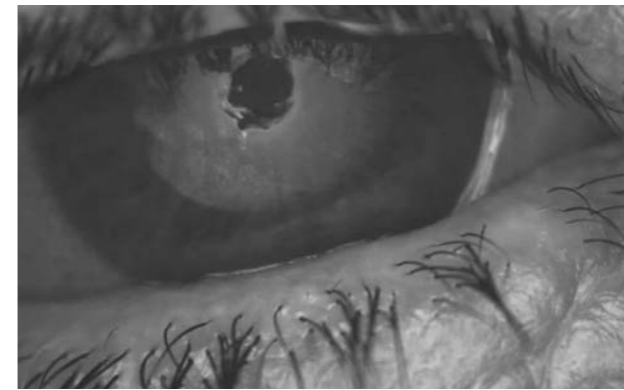
Eyelight laser, eye care and research centre, Pune India

Patient's description

- Sixty-five year aged woman has compound myopic astigmatism.
- No history of contact lens wear.
- She does not report other systemic diseases or taking other drugs on a regular basis.

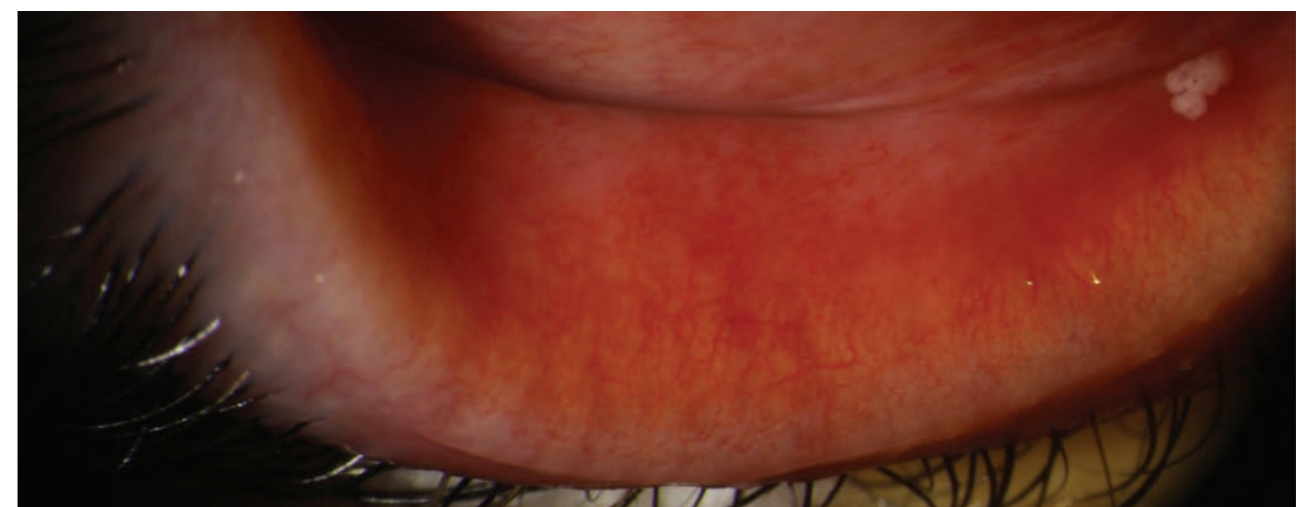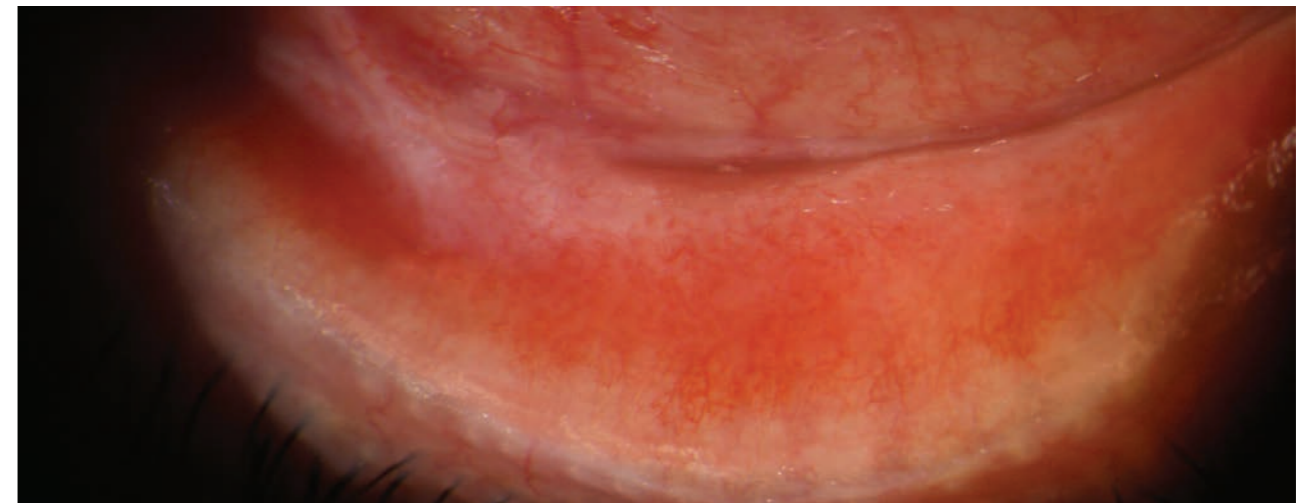
Dysfunction description

- She presented to clinic with complaints of redness, foreign body sensation and mucoid discharge in both eyes since 2 months.
- Slit lamp bio-microscopy showed hypertrophied, rounded lid margins with lid odema. Inner lid margin shows telangiectatic blood vessels of both upper and lower lids.
- Ocular surface shows diffuse conjunctival congestion and chemosis with partial obliteration of the inferior fornix (stage I forniceal shortening as per Fosters' grading).
- Cornea is clear though lustreless.

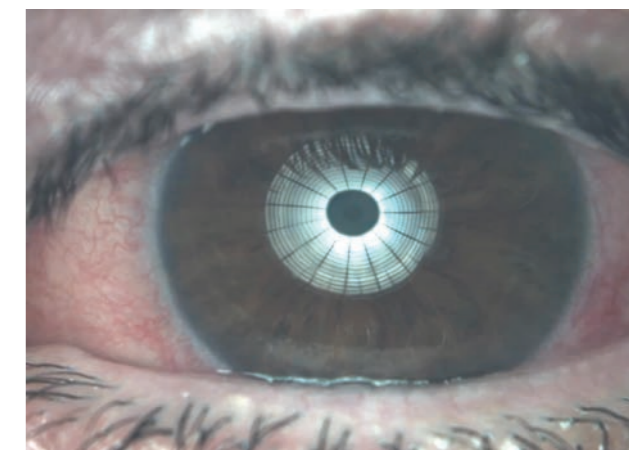
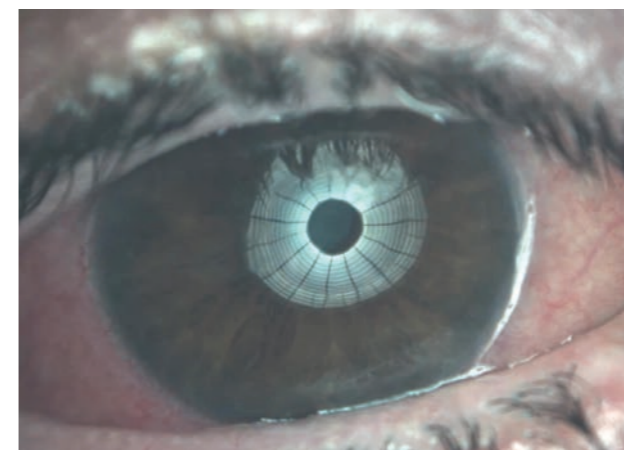
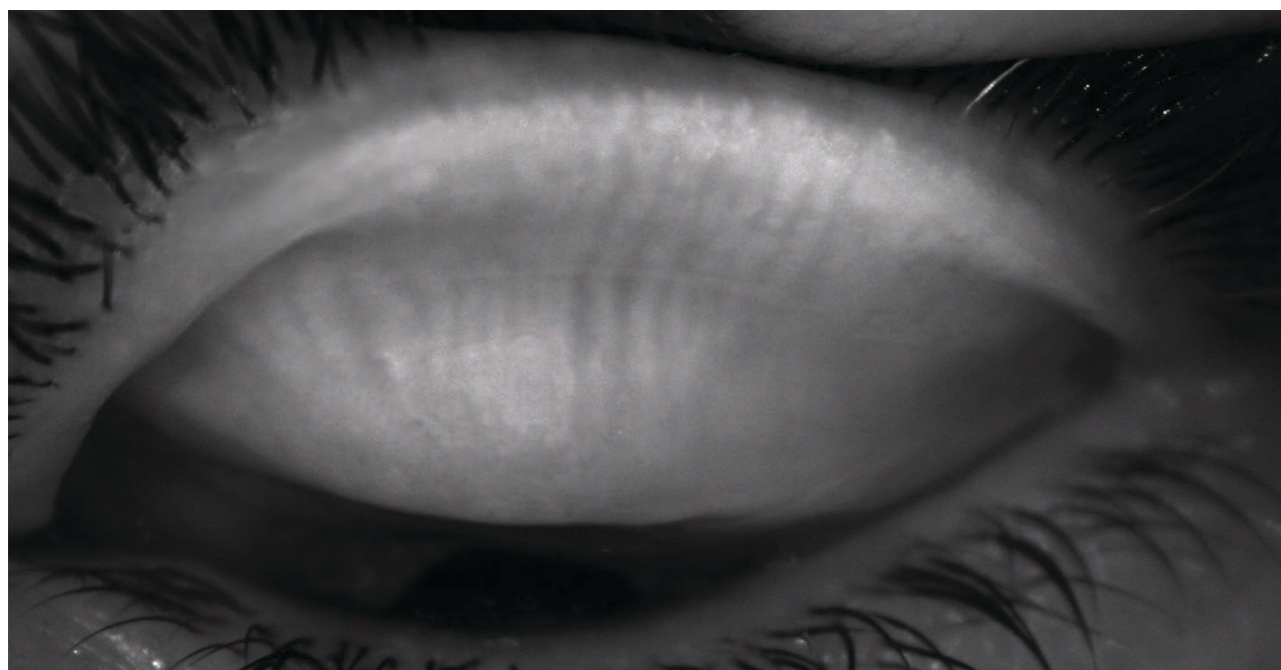
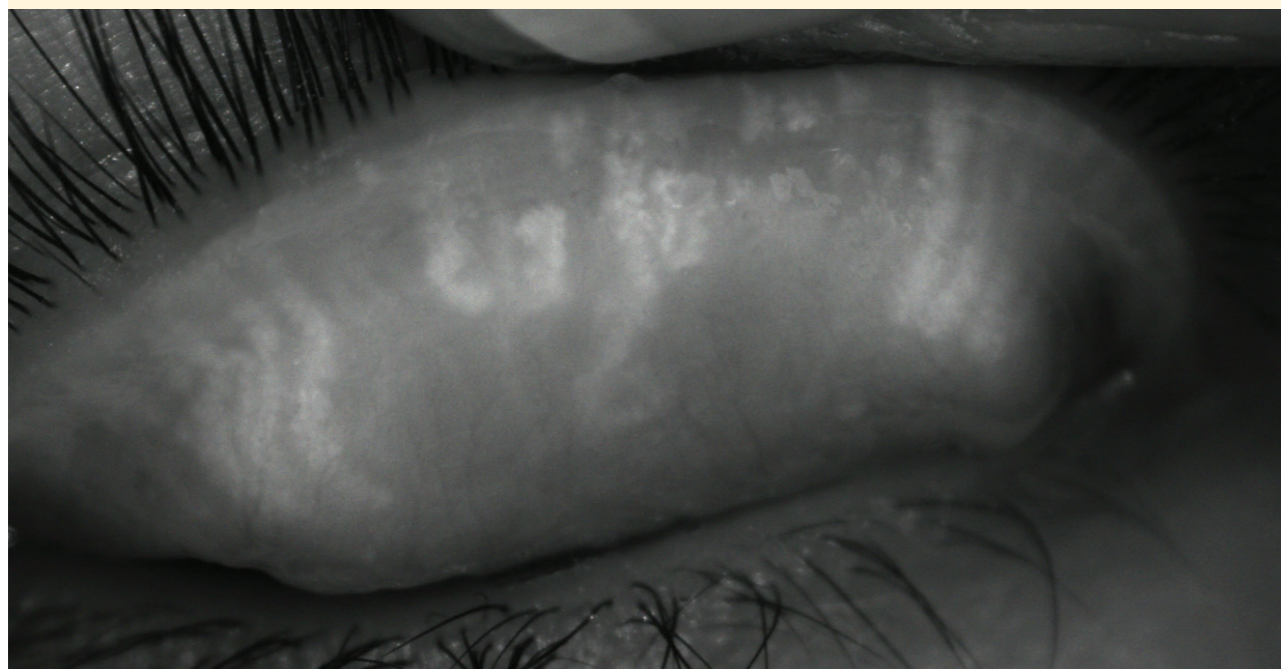
Exams comments

The patient is affected by ocular mucous membrane pemphigoid (Stage I) confirmed by conjunctival biopsy and immunoperoxidase staining. Clinical exam shows severe dry eye syndrome secondary to autoimmune disease with poor aqueous, mucin and lipid component. Meibomian glands are not visible on slit lamp examination due to excess conjunctival chemosis, however, they are partially imaged (figure 1) on meibography. While inactive, the disease may masquerade as conjunctivitis or Meibomian gland disease. It is prudent to note that conjunctival pathologies may restrict the meibomian gland imaging and the results should be interpreted with caution. The therapy for Ocular Mucous membrane pemphigoid involves systemic immunomodulatory agents along with artificial tears and ointment based lubricants without preservatives. In addition, topical steroids and topical cyclosporine. Are prescribed to control the surface inflammation.



Upper eyelid examination



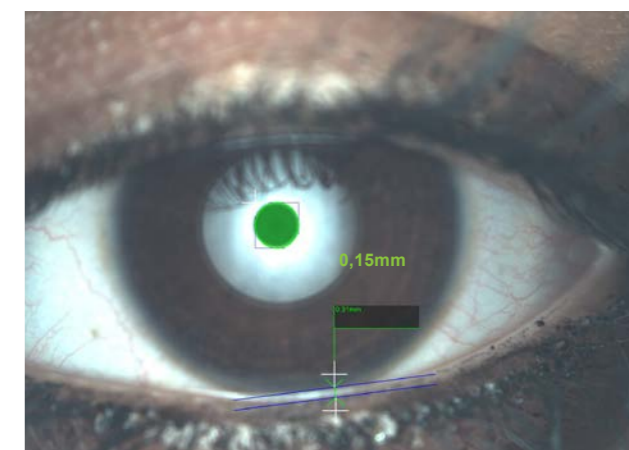
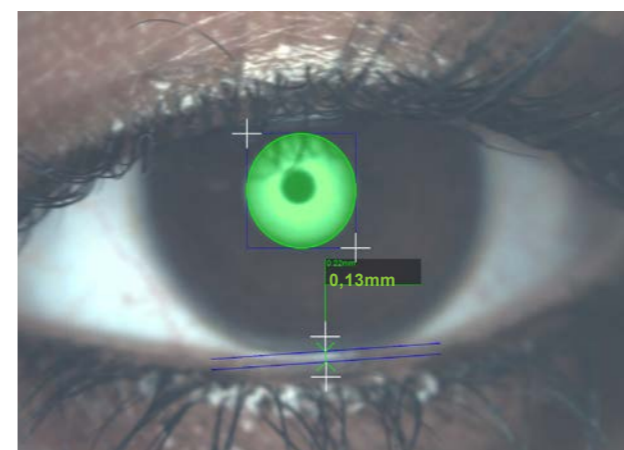
OSDI: 72.9

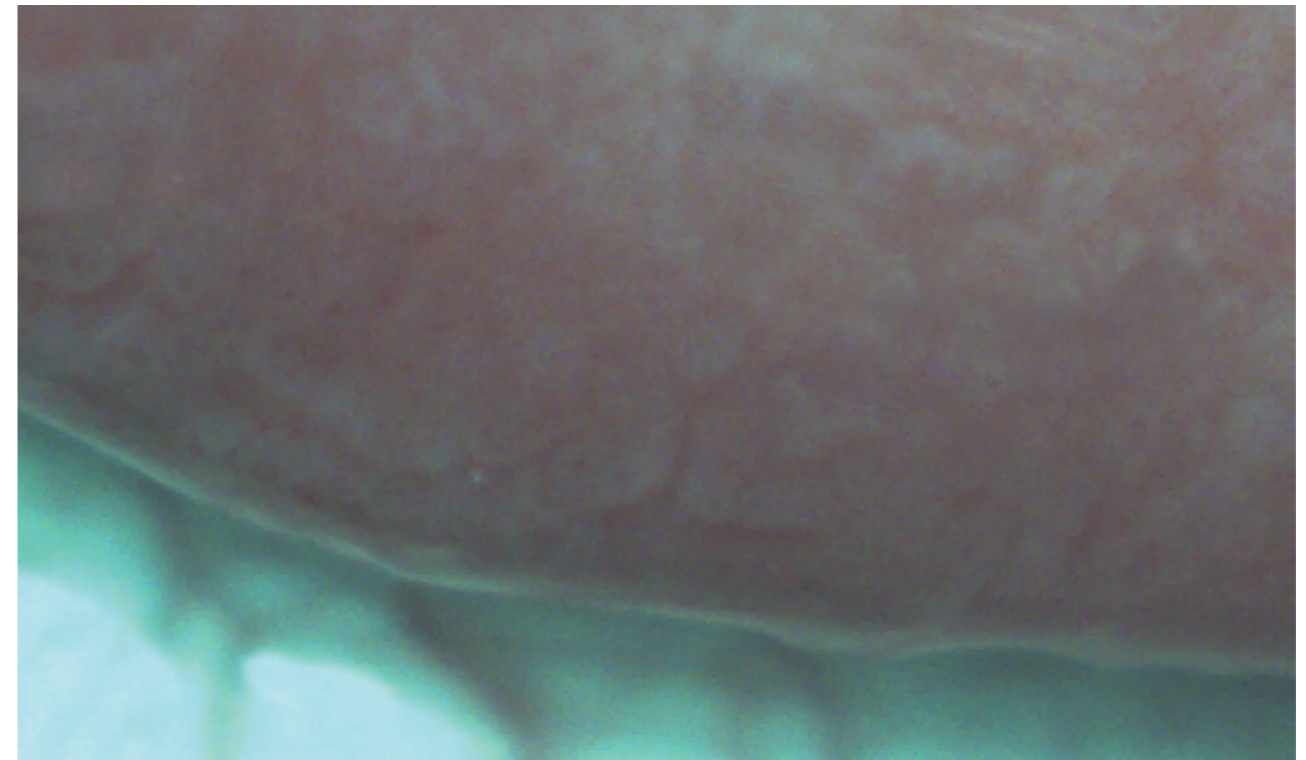

Values

Interferometry: OD 80 nm OS: 30-80 nm
Tear Meniscus: OD: 0,13 mm, OS: 0,15 mm

NIBUT: OD 4 sec, OS: 7.1 sec

Meibography: OD 31% loss, OS: 27% loss



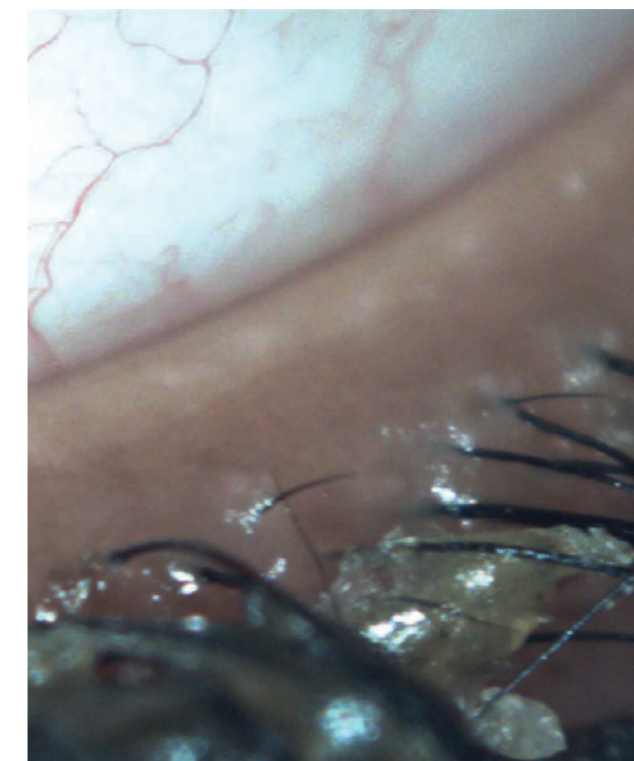


Values

Interferometry: OD 30nm OS: 30 nm

Tear Meniscus: OD: 0.22 mm, OS: 0.31 mm

Meibography: OD 23% loss, OS: 28% loss



Case 2 – Blepharitis

Dr. Natasha Pahuja

Eyelight laser, eye care and research centre, Pune India

Patient Description

- Twenty-two year aged man has compound myopic astigmatism.
- Wears monthly-wear disposable contact lenses.
- He does not report other systemic diseases or taking other drugs on a regular basis.
- He does not give history of any ocular surgery.

Dysfunction description

He presented to clinic with complaints of ocular discomfort, mild irritation and occasional redness in both eyes since 4 months. Slit lamp bio-microscopy showed hypertrophied lid margin, superficial non destructive dermatitis with eczema like inflammation characterised by vascular congestion on the lid margin of both upper and lower lids. Crusting and scales are seen at the base of eye lashes. Parakeratosis and healed ulcerative lesions on anterior lid margins. Ocular surface showed papillary hypertrophy on the tarsal conjunctiva. Cornea is clear.

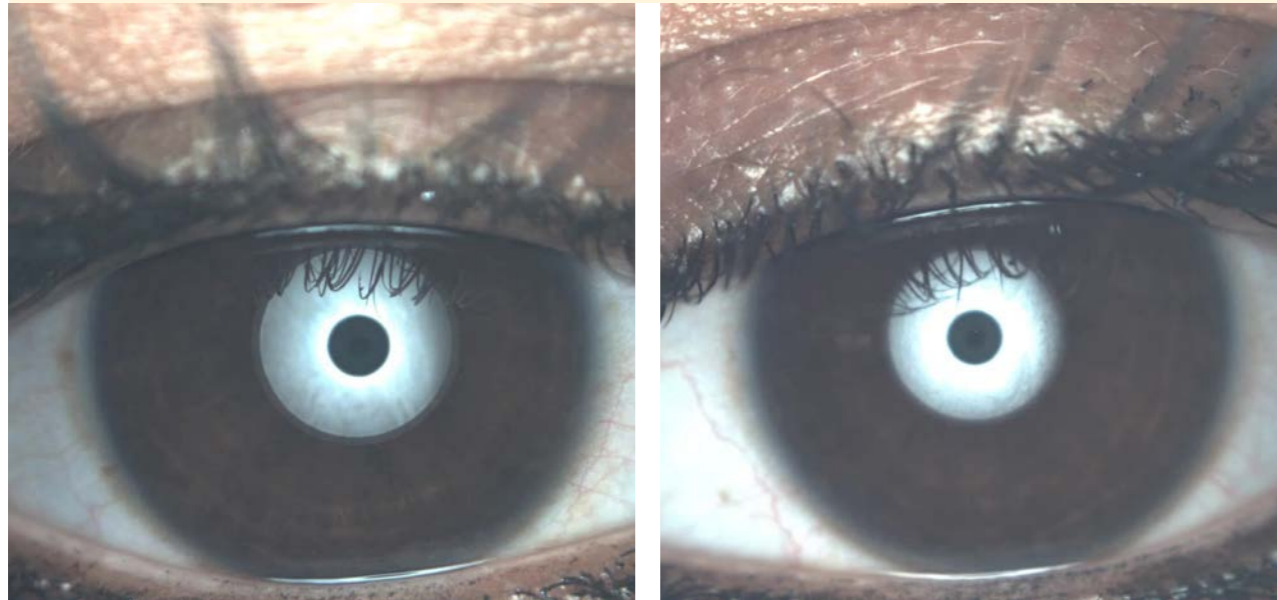
Exam Description

The patient is affected by Follicular Ulcerative Blepharitis (Duke-elder and MacFaul classification). Clinical exam shows acanthosis, Parakeratosis crusting and scales are seen at the base of eye lashes.

- In addition topical steroids and topical Cyclosporine A are prescribed to control the surface inflammation.
- Change from monthly-wear disposable to daily-wear disposable lenses is advised as contact lens may act as a reservoir for debris and can lead to formation of more deposits at the lid margin.

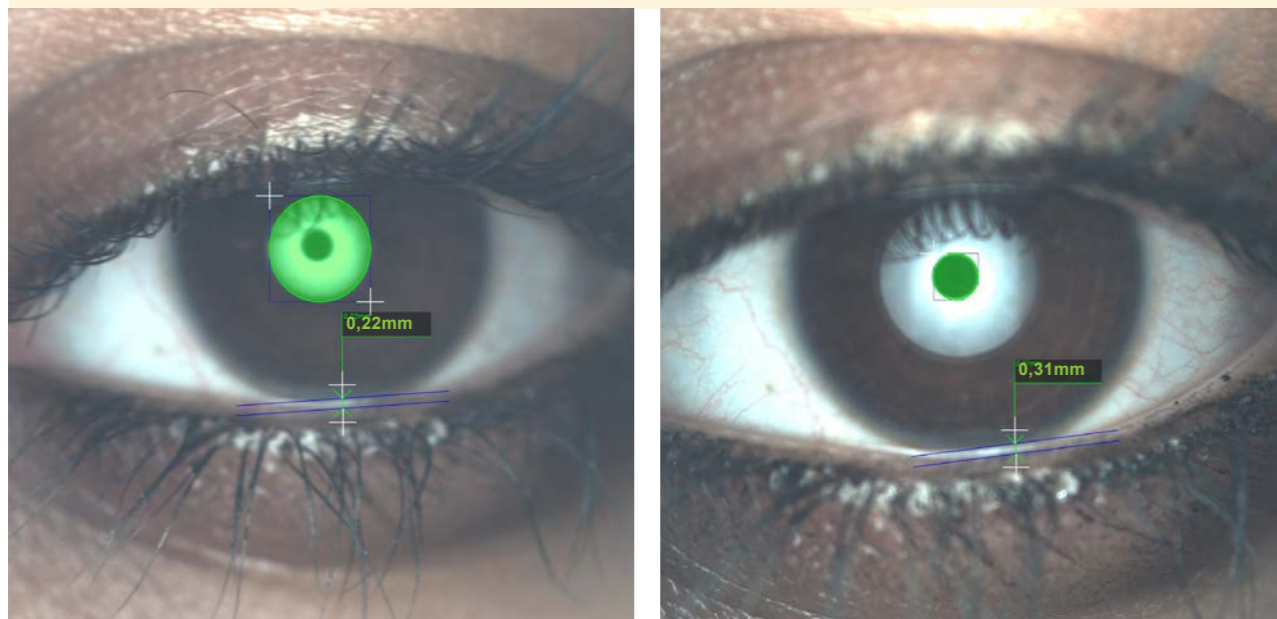
Lipid Layer Analysis

The Lipid analysis was good for both eyes with values less than <30nm



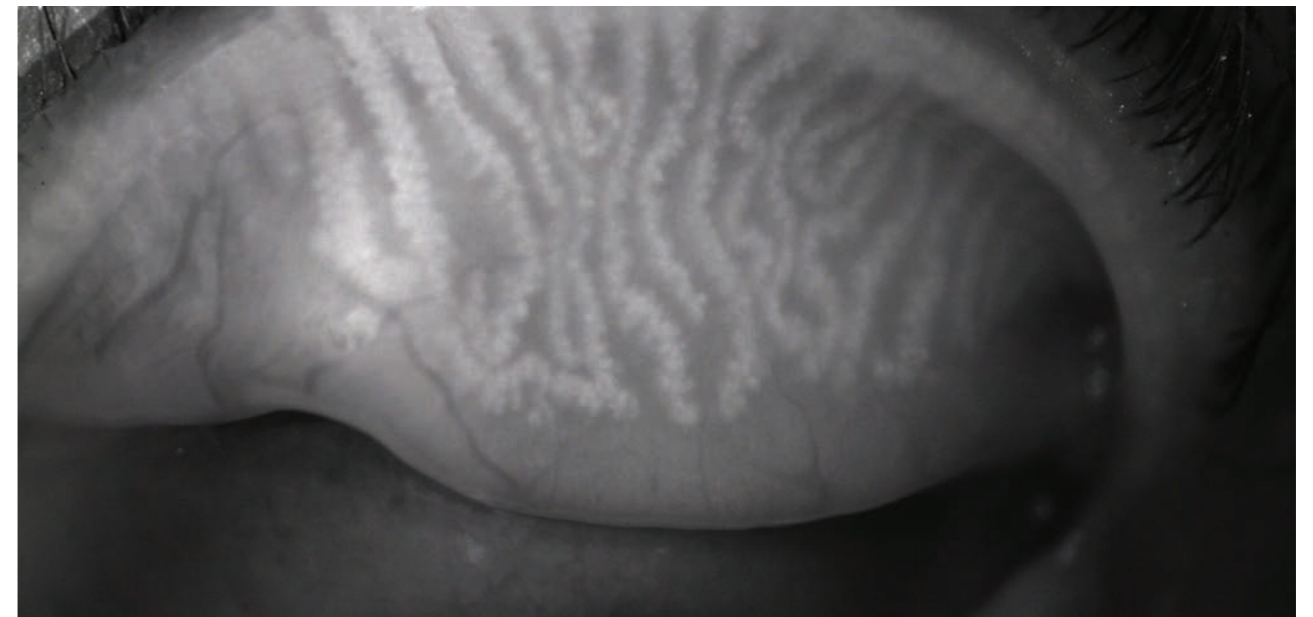
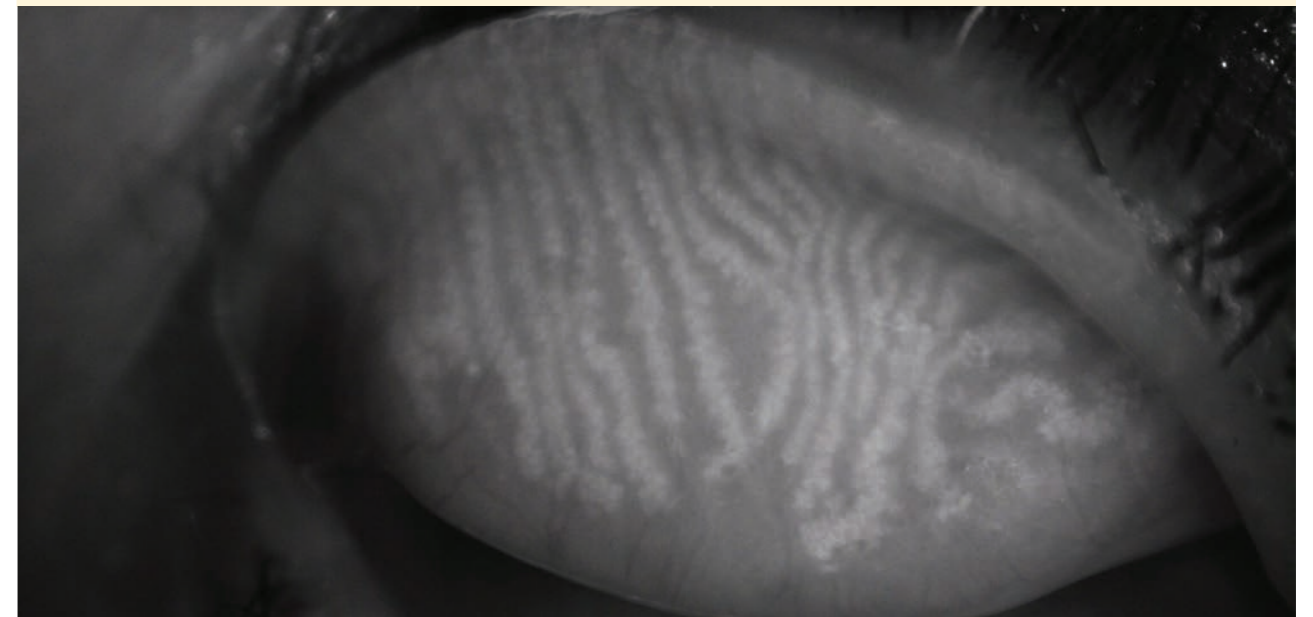
Tear Minuscus

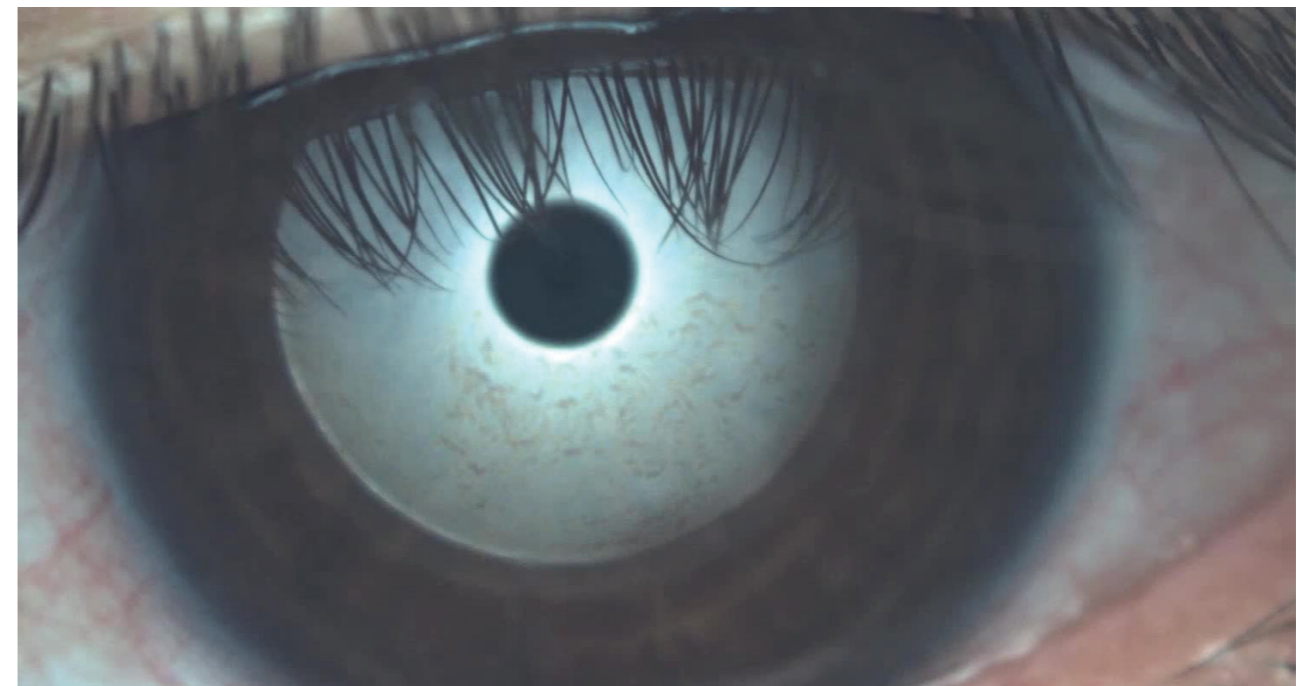
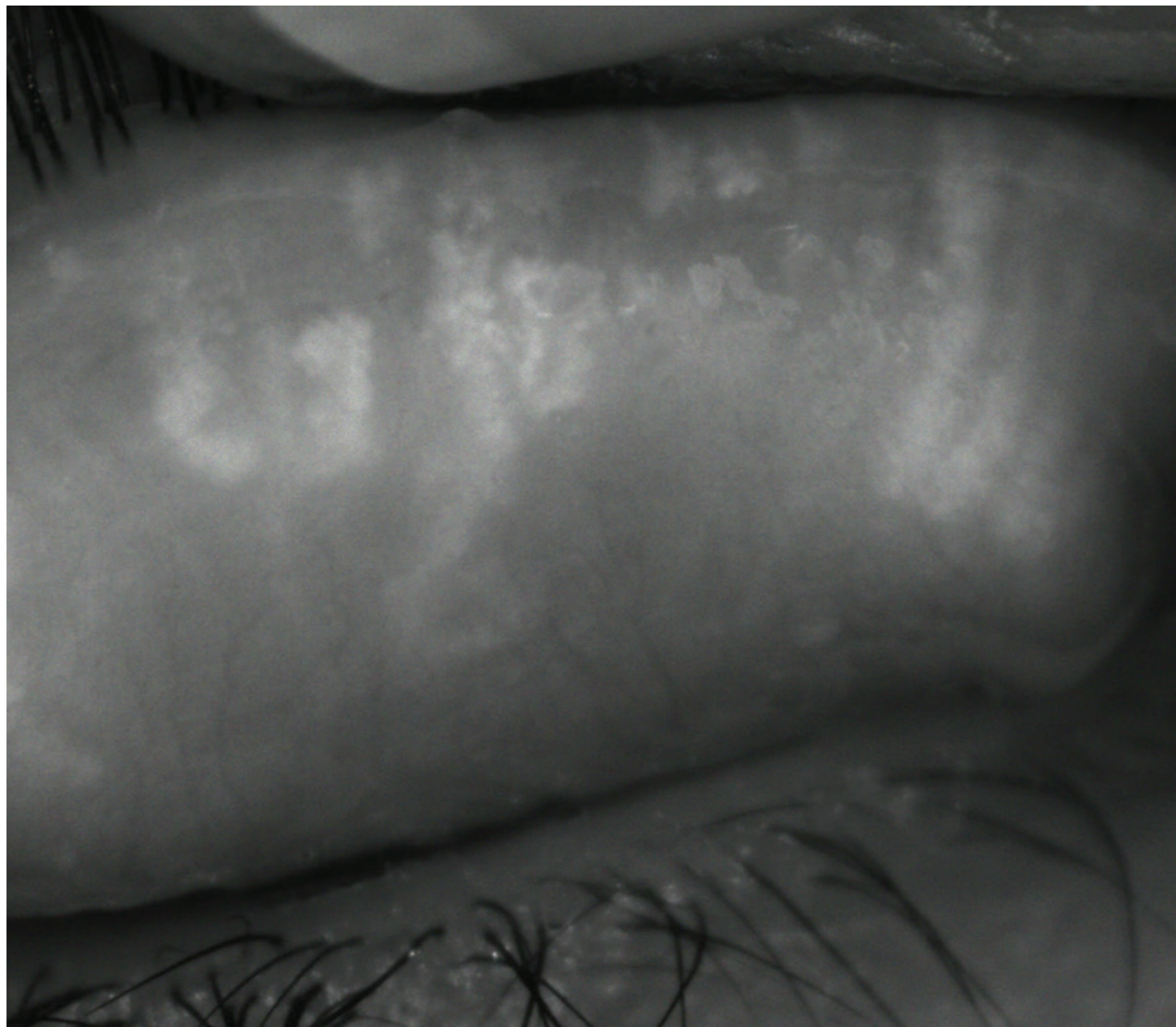The Ocular surface analyser showed tear meniscus height for OD eye with 0,22 mm height and for the OS eye at 0,31 mm



MGD

The mgd analysis showed a loss of 23% for OD eye and 28% for OS eye





Case 3 – Meibomian gland dysfunction (MGD)

Dr. Natasha Pahuja

Eyelight laser, eye care and research centre, Pune India

Patient's description

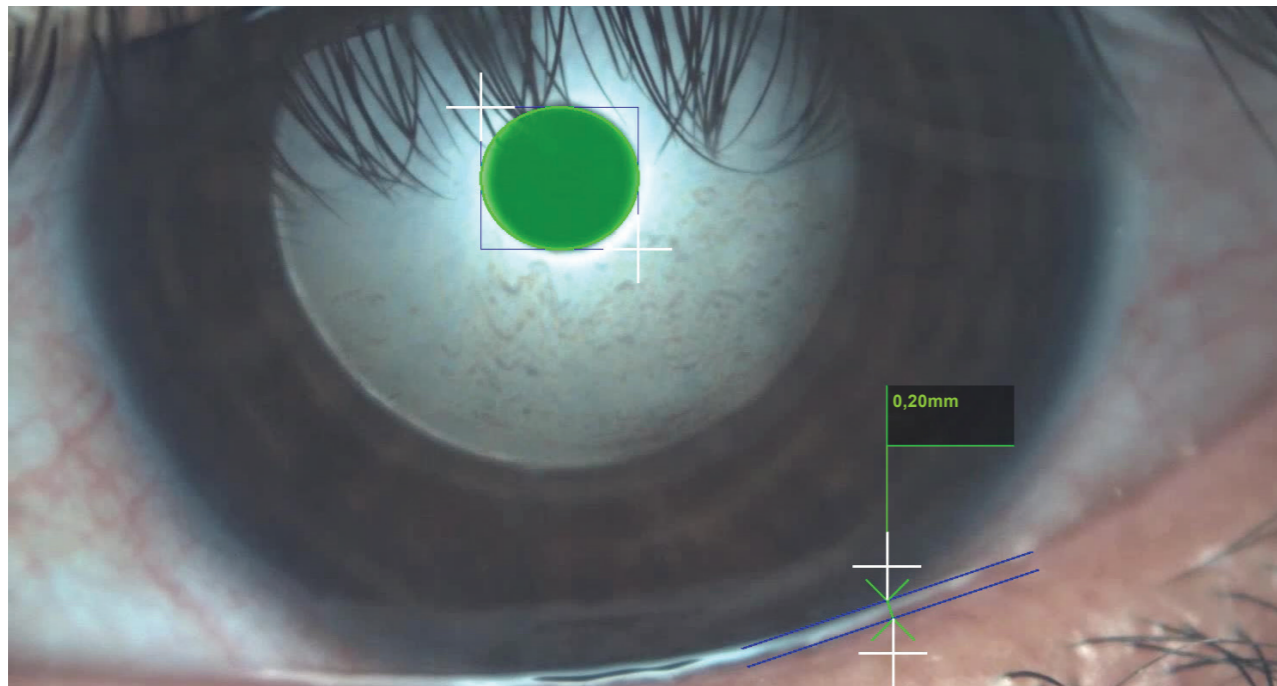
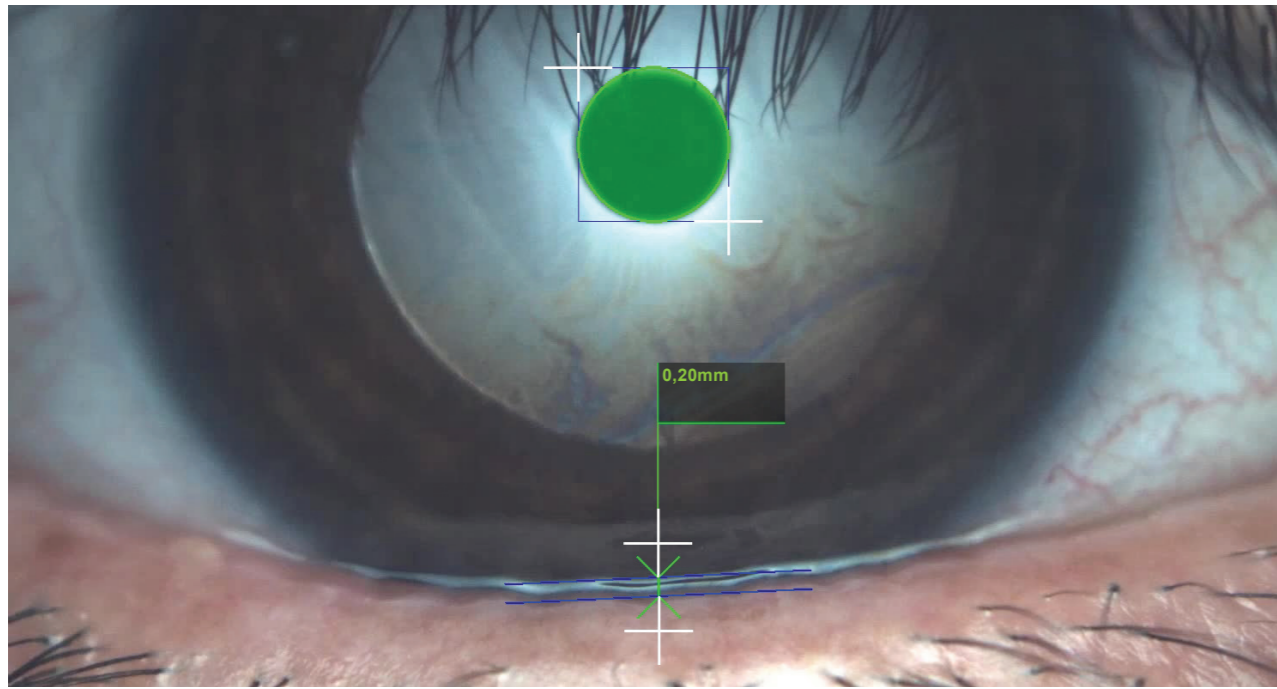
- Forty-one year aged woman post cataract surgery with multifocal intraocular lens.
- She does not report other systemic diseases or taking other drugs on a regular basis.
- She does not give history of any other surgery.

Dysfunction description

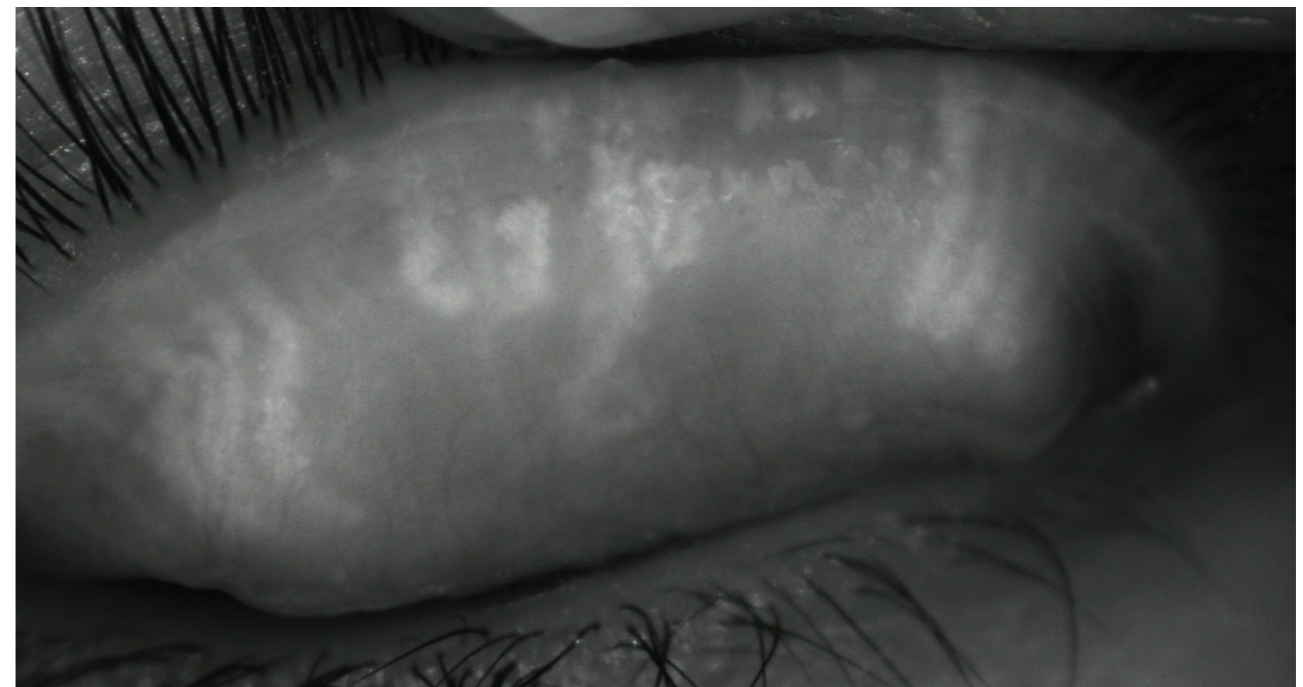
She presented to clinic with complaints of glare, mild ocular discomfort, occasional pain and foreign body sensation in both eyes 4 weeks after bilateral cataract surgery. Slit lamp bio-microscopy showed mild hypertrophy of lid margin with vascular congestion on the lid margin of both upper and lower lids. Ocular surface showed papillary hypertrophy on the tarsal conjunctiva. Pre-corneal tear film showed tear film debris. Cornea is clear. Anterior chamber was quiet and of normal depth and well centred multifocal intraocular lens in both eyes.

Exam Description

The patient is affected by Meibomian gland dysfunction (MGD) with evaporative dry eye disease. Clinical exam shows truncated and engorged meibomian glands with multiple areas of gland drop outs. While her Schimers I was 28 mm and 30 mm her TBUT was 5 seconds and 4 seconds in right eye and left eye, respectively. It is prudent to note that the dry eye disease and MGD were not evaluated/imaged prior to cataract surgery. The dry eye-like symptoms associated with MGD overlap the symptoms of unhappy multifocal IOL patient. In the absence of qualitative and quantitative assessment, early stages of disease may be missed only to manifest later with increased symptoms after progression.



Right and left upper eyelid examination



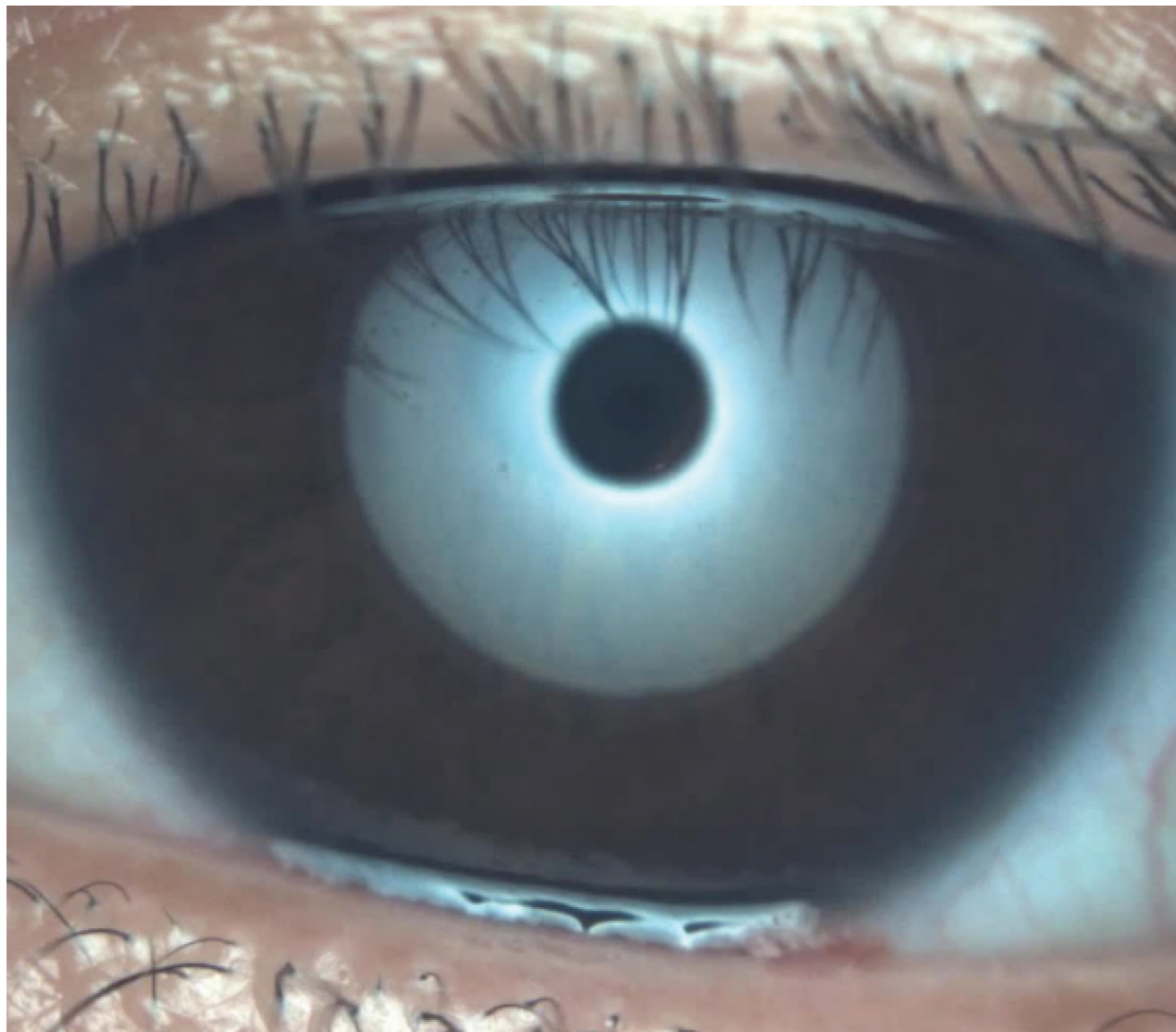Values

OSDI: 20.8

Interferometry: OD 30 nm OS: 30 nm

Tear Meniscus: OD: 0,20 mm, OS: 0.20 mm

Meibography: OD 42% loss, OS: 60% loss

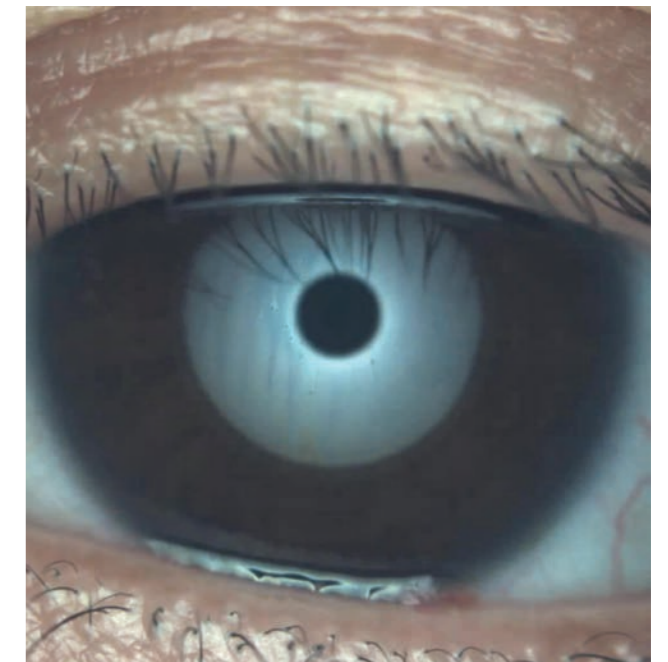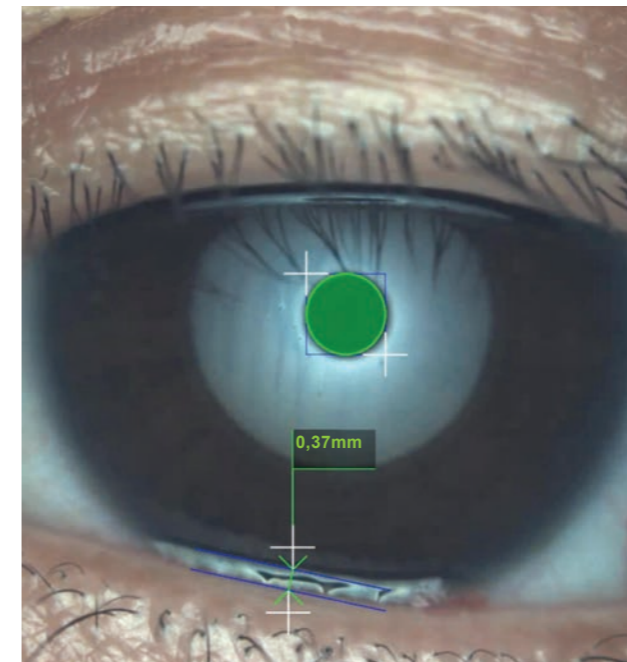


Case 4 – Evaporative Dry Eye

Dr. Luca Vigo
 Centro Oftalmo Chirurgico Carones
 Italy

Patient's description
 30-year-old woman. Short-sighted and astigmatic, contact lens wearer. She regularly takes the contraceptive pill for several years, while she does not report other systemic diseases or taking other drugs on a regular basis.

Dysfunction description
 For some months she has been complaining of difficulties in using lenses, significant dryness during the night and upon awakening. During the day she has symptoms such as burning, itching, a foreign body sensation, especially when working on a computer or in an air-conditioned environment. On the objective examination, she shows a transparent and reflecting cornea, a conjunctival staining value between 1 and 2 with hyperaemia in the fornix and in the inner chant.



Exams comments

The patient is affected by an evaporative dry eye with poor lipid component and dysfunction of the Meibomian glands.

The cause is presumed to be hormonal (estrogen-progestin) and the therapy involves the use of tear substitutes with fatty acids or stabilizing the tear film and the mechanical / instrumental stimulation of the Meibomian glands with their unblocking (heat and massage) and pulsed light.


Osmolarity values are OD 298mOsm/L, OS: 310 mOsm/L

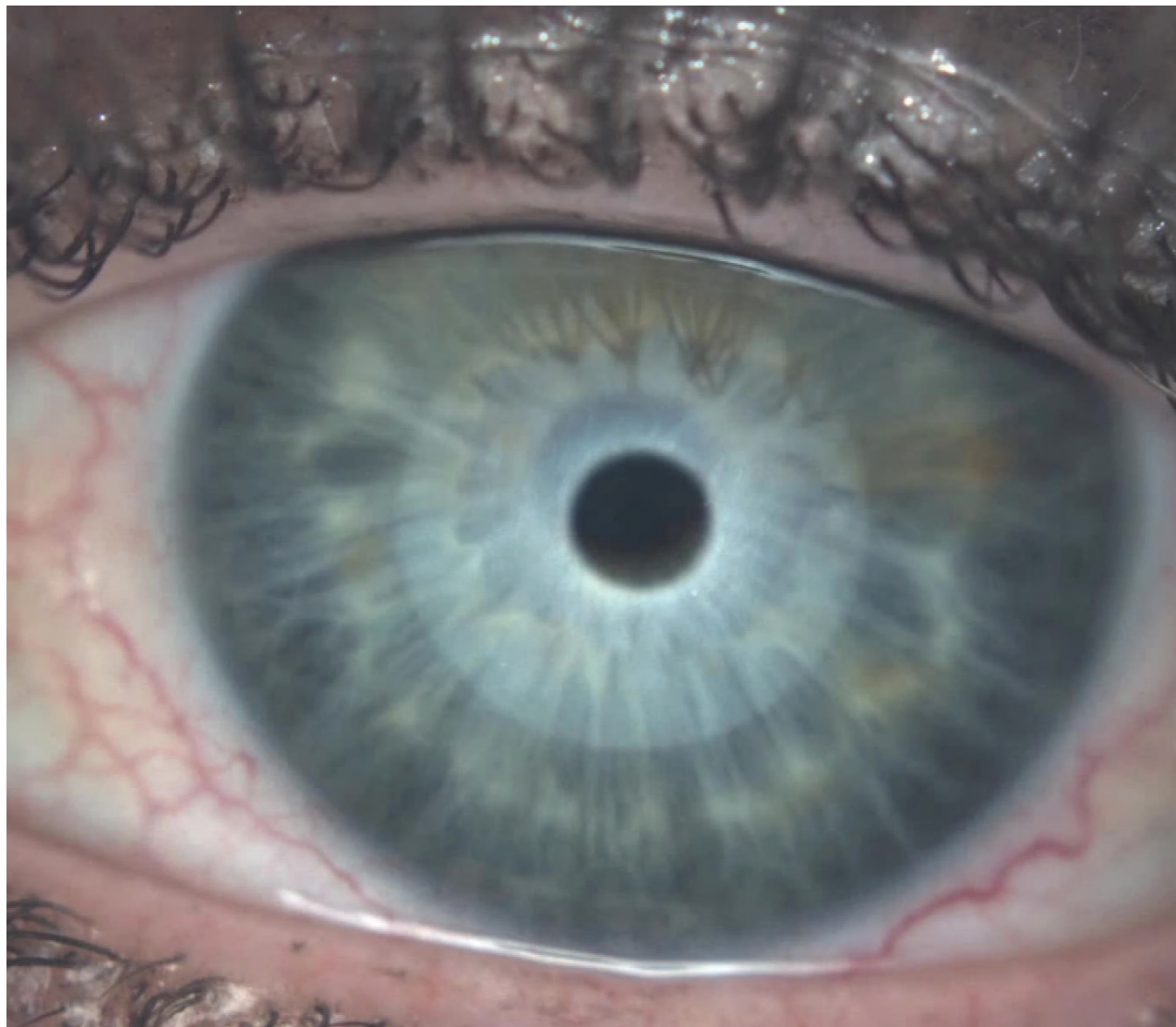
Inflammadry test: negative

Values

Interferometry: OD 30-80 nm OS: 30 nm
 Tear Meniscus: OD: 0,37 mm, OS: 0,35 mm

NIBUT: OD 8,6 sec, OS: 7,5 sec
 Meibography: OD 15% loss, OS: 22% loss



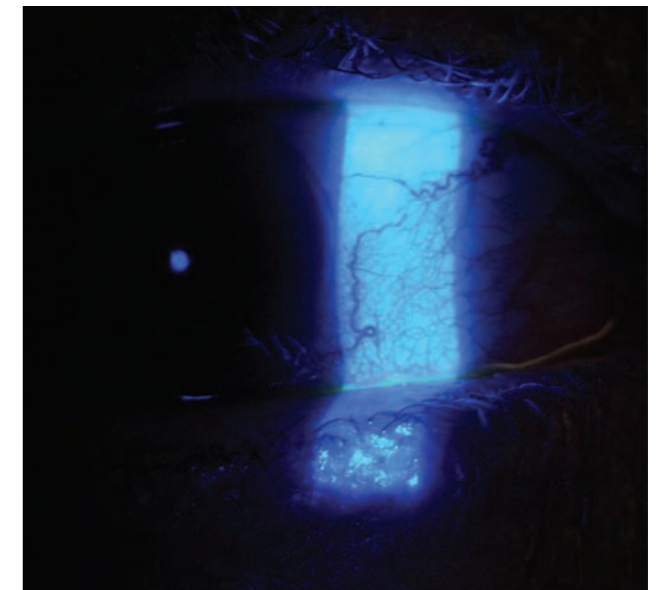
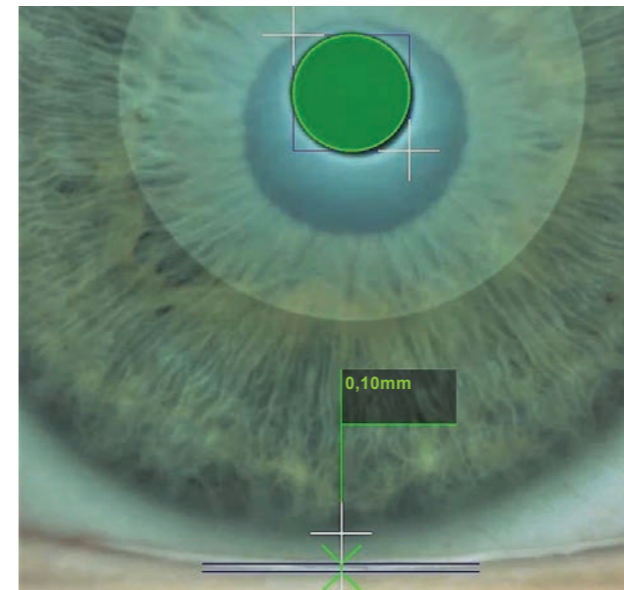


Case 5 – Hypo lacrimation due to aqueous deficit

Dr. Luca Vigo
 Centro Oftalmo Chirurgico Carones
 Italy

Patient's description
 45-year-old woman. Emmetrope with an initial presbyopia. She does not take hormone therapy but refers to general feeling of discomfort, joint pain and sometimes even dryness in the mouth and airways.

Dysfunction description
 She for some months complains of photophobia, burning, sensation of a foreign body, an important redness that worsens during the day as well as symptoms. The patient after systemic investigations is affected by suspected rheumatoid arthritis and autoimmune immunological disorders still to be defined. Ocular objective examination: modest suffering of the corneal surface (diffuse paracentral lower epitheliopathy), especially bulbar conjunctival hyperaemia, corneal and conjunctival staining between 2 and 3.



Exams comments

She presents a framework compatible with an important hypo lacrimation for aqueous deficiency due to poor function of the lacrimal gland.

Systemic therapy is entrusted to the immunologist, while at the local level corticosteroid collides are needed for cyclic or cyclosporine use in a chronic and continuous way. Tear substitutes based on hyaluronic acid or carboxymethyl cellulose with high molecular weight or high concentration and tear gels at night are also required.

Osmolarity: OD 320 mOsm/l OS 315 mOsm/l

Inflammadry test: positive

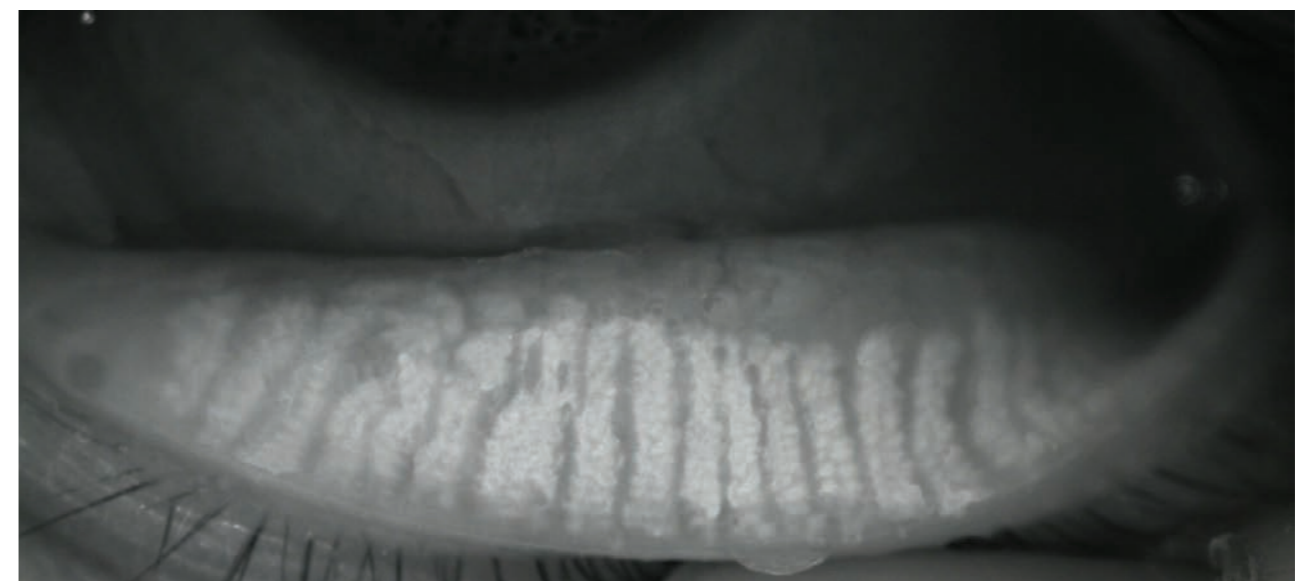
Values

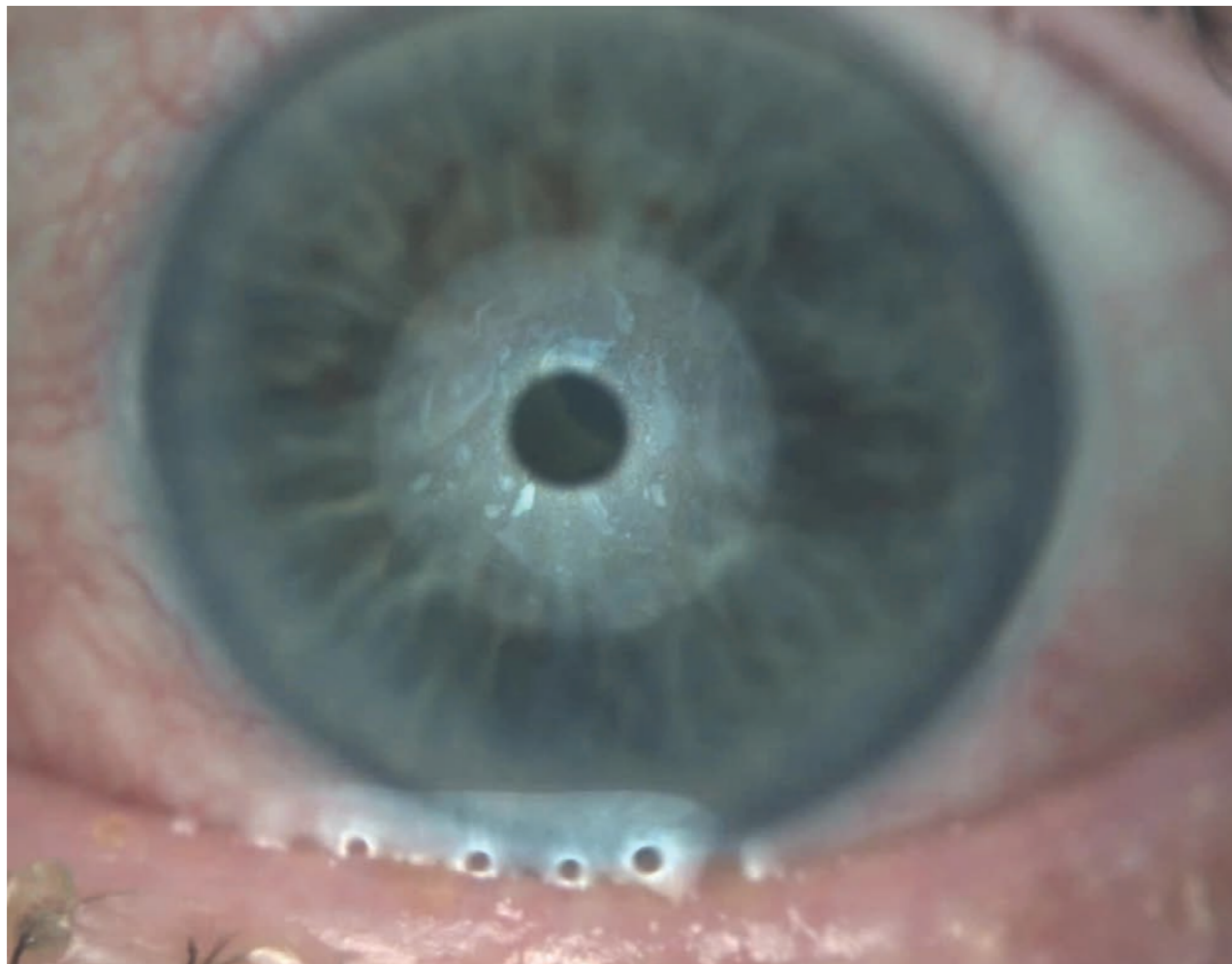Interferometry: OD 80-120 nm, OS: 80-120 nm

NIBUT: OD: 10.5 sec OS: 11.3 sec

Tear Meniscus: 00 < 0,1 mm

Meibography: OD 10% loss OS 5% loss





Case 6 – Evaporative Dry Eye with poor lipid component

Dr. Luca Vigo

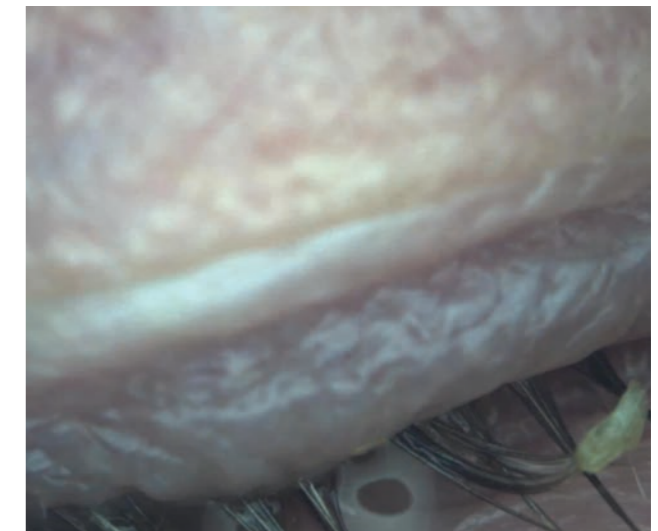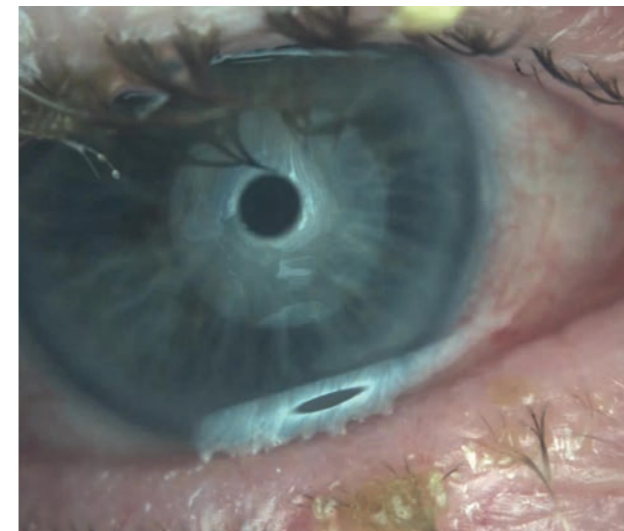Centro Oftalmo Chirurgico Carones
Italy

Patient's description

54-year-old man. With mild hypermetropia associated with presbyopia. He uses glasses for reading only. He does not report systemic diseases for which he takes drugs but in recent times a difficulty in the digestion of certain foods with suspected food intolerances.

Dysfunction description

He complains at eye level redness already upon waking with modest secretion and difficulty in opening the eyes with sensation of a foreign body. During the day he refers to itching in the eyes and eyelids and episodes of excessive lacrimation. For some months the symptoms have worsened with increased secretion even during the day between the eyelashes and thinning of the same. Objective examination: transparent cornea, initial crystalline sclerosis, conjunctival hyperaemia marked above all in the lower fornix and inflammation of the palpebral edge with alterations in the profile and tortuosity of the Meibomian glands and dilatation or atresia of some orifices. Corneal staining 1, conjunctival 3.



Exams comments

Osmolarity: OD 295 mOsm/L OS: 306 mOsm/L

Inflammadry test: positive

The patient suffers from an evaporative type of dry eye with a low lipid component due to an important deficiency of the function of the Meibomian glands.

Systemic investigations have identified digestive difficulties due to liver changes and suspected partial intolerance to dairy products and other substances including gluten.

The therapy consists of a systemic level in avoiding harmful foods and restoring a balance of the gastro enteric (lactic supplements and ferments), while at the local level surface topical corticosteroids used cyclically, tetracycline ointment at night for medium-long periods, substitutes tears based on fatty acids, disinfection and daily cleaning of the eyelid edge with special wipes, stimulation of the Meibomian glands with heat and pulsed light.

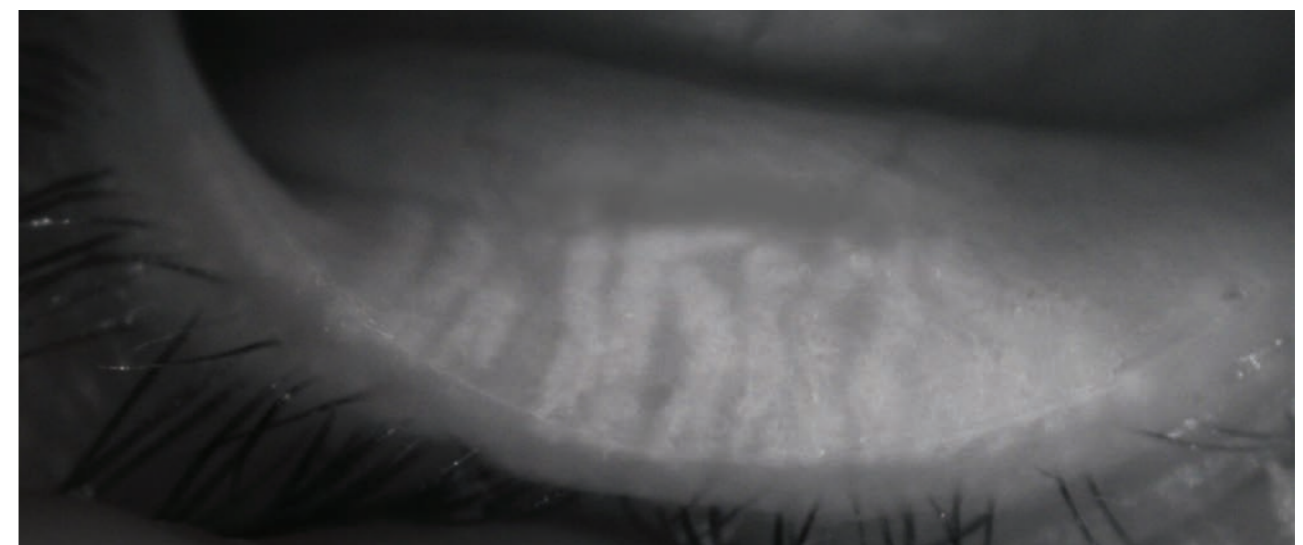
Values

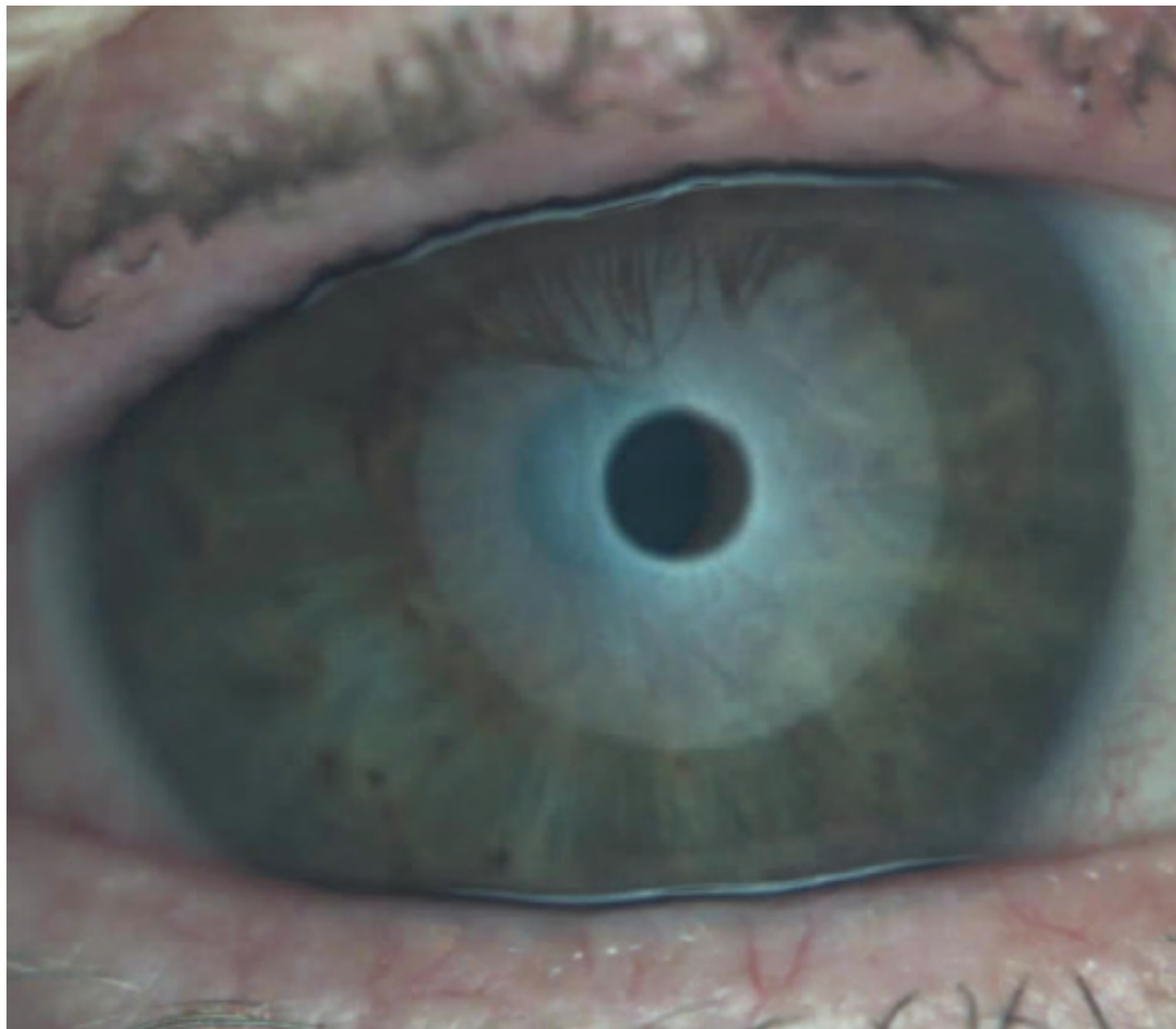
Interferometry: OO 30 nm

NIBUT: OD 9,7 sec, OS: 8,2 sec

Tear Meniscus: OD: 0,8 mm, OS: 0,7 mm

Meibography: OD 35% loss, OS 45% loss





Case 7 – Meibomian Glands Dysfunction

Dr. Luca Vigo

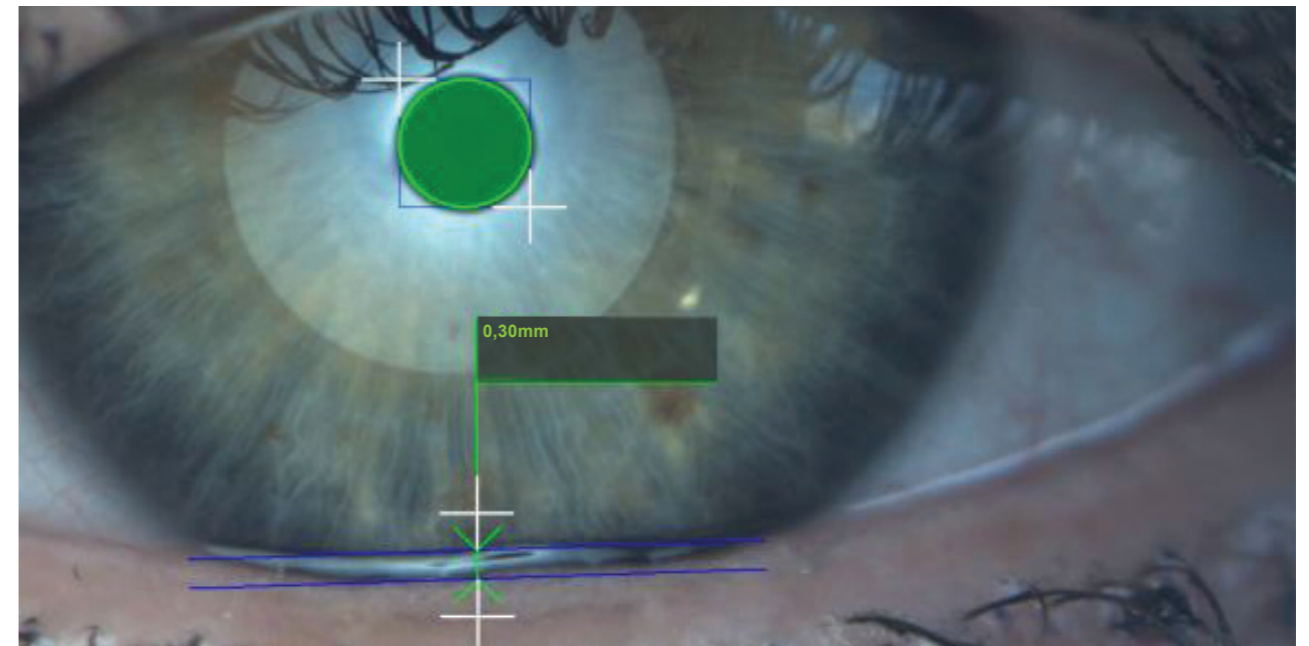
Centro Oftalmo Chirurgico Carones
Italy

Patient's description

47-year-old woman.
Short-sighted and slightly astigmatic,
wearer of contact lenses.
She does not present known pathologies,
but it is in chronic therapy with estrogen-
progestin.

Dysfunction description

For some months she has reported difficulties
in the use of lac and the appearance of
relapsing chalazion and sties.
She also complains of a dry eye on waking and
redness and itching in the eyes during the day.
An upper right eye eyelid chalazion and a left
eyelid lower eyelid is present.
Objective examination: transparent cornea and
crystalline, conjunctival hyperaemia above all
in the archway with chronic inflammation
of the conjunctival and palpebral edge.
Corneal staining 0, conjunctival 2.



Exams comments

Osmolarity: OD 312 mOsm/l, OS 310 mOsm/l
Inflammadry test: positive

The patient suffers from dysfunction of the Meibomian glands probably of hormonal nature. Since systemic hormone therapy cannot be stopped and at the local level tetracycline ointment therapy is necessary for a few weeks, combined with topical corticosteroid therapy. They are also useful artificial tears with fatty acids, a thorough cleaning and disinfection of the palpebral edge daily and dry warm compresses to solve and mature the chalazion and the sty.

A mechanical cleaning of the Meibomian glands and their subsequent stimulation by pulsed light could also be very effective.

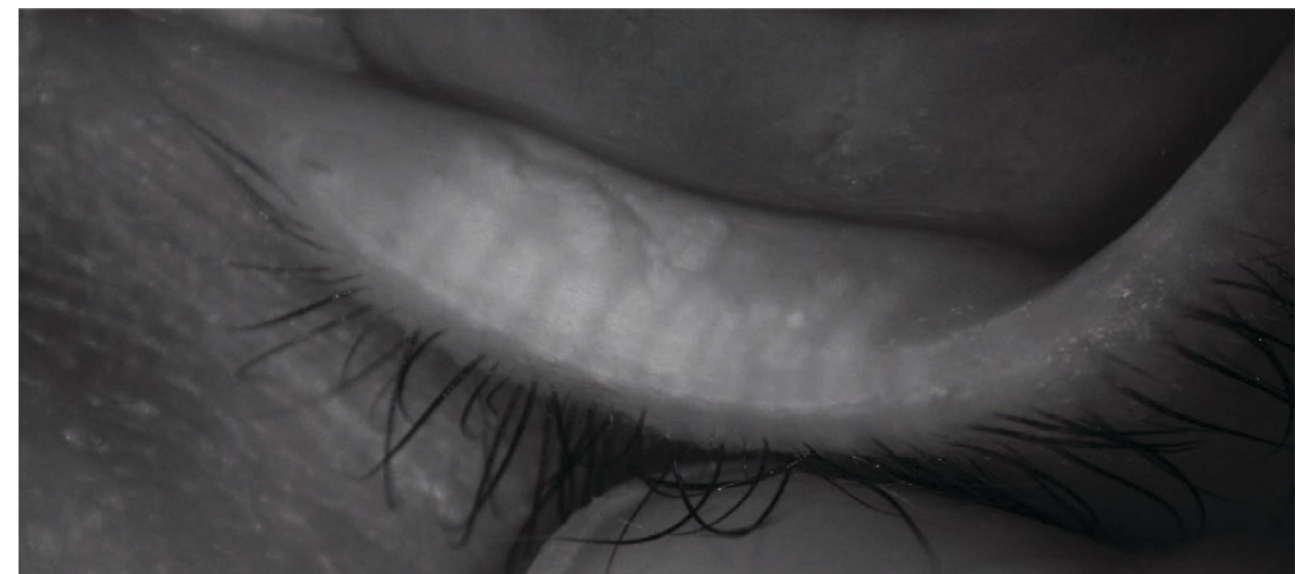Values

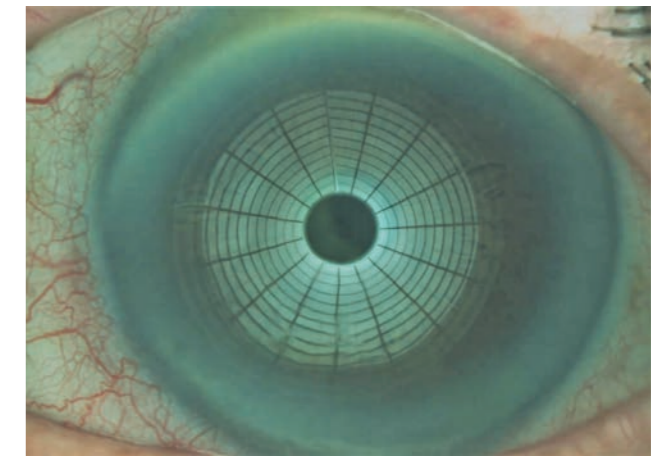
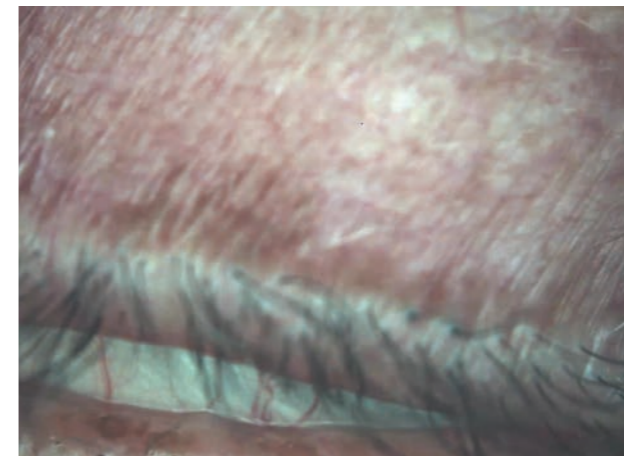
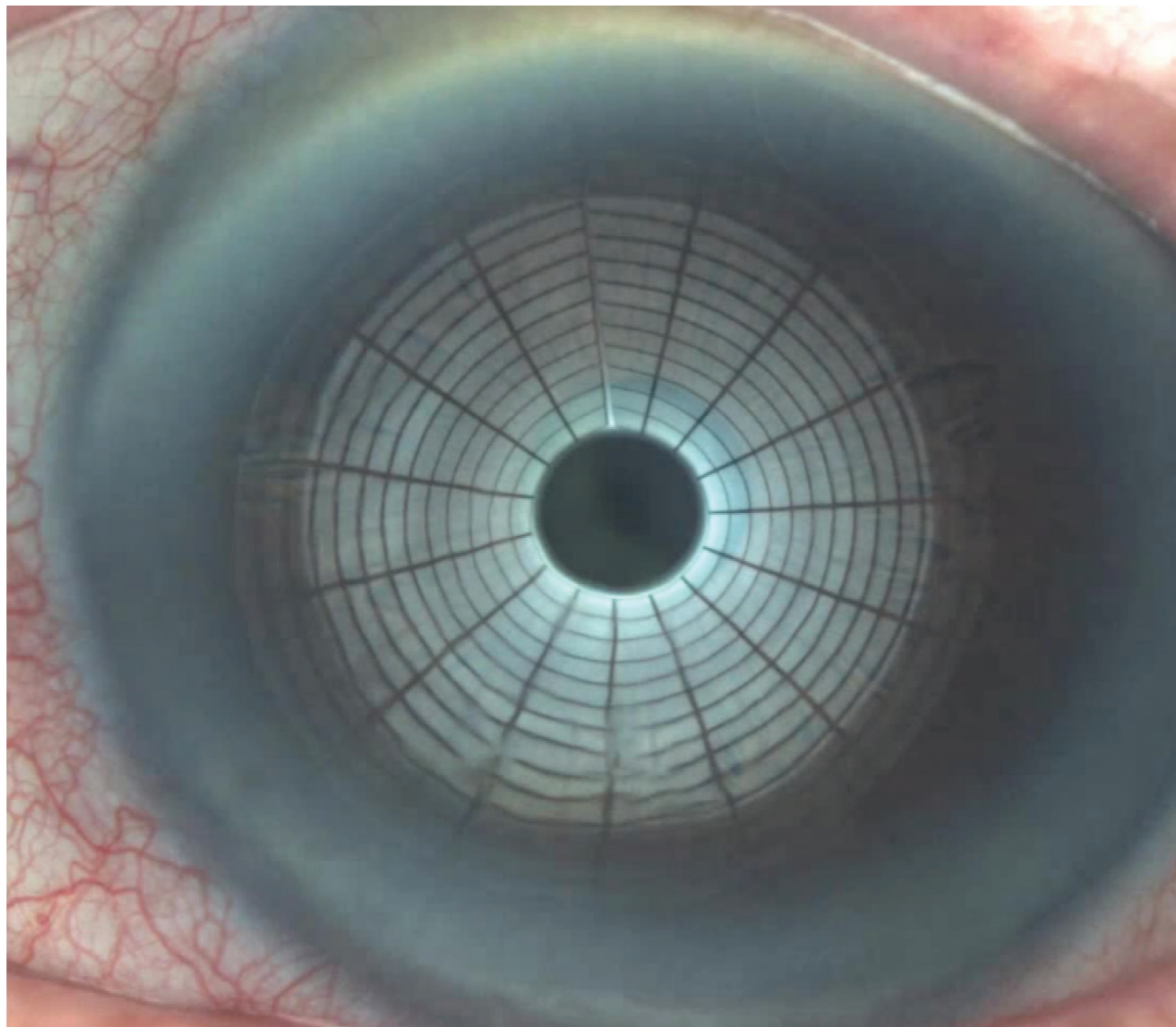
Interferometry: 15 nm OD, 30 nm OS

NIBUT: OD 5,6 sec, OS: 6,7 sec

Tear Meniscus: OD 0,3 mm, OS : 0,5 mm

Meibography: OD 43% loss, OS 47% loss





Exams comments

Instrumental examinations: Osmolarity: OD. 317 mOsm/L, OS 320 mOsm/L

Inflammadry test: positive

The patient suffers from dry eye due to excessive evaporation and poor lipid component due to an altered function of the Meibomian glands due to structural and mechanical deficiency of both upper and lower eyelids. The therapy consists in the surgical restoration of an adequate eyelid anatomy (upper and lower blepharoplasty).

At the local level, on the other hand, the therapy is against blepharitis and related chronic inflammation: tetracycline ointment, topical corticosteroids, eye washings and disinfection of the eyelid border and daily use of artificial tears with fatty acids or tear film stabilizers.

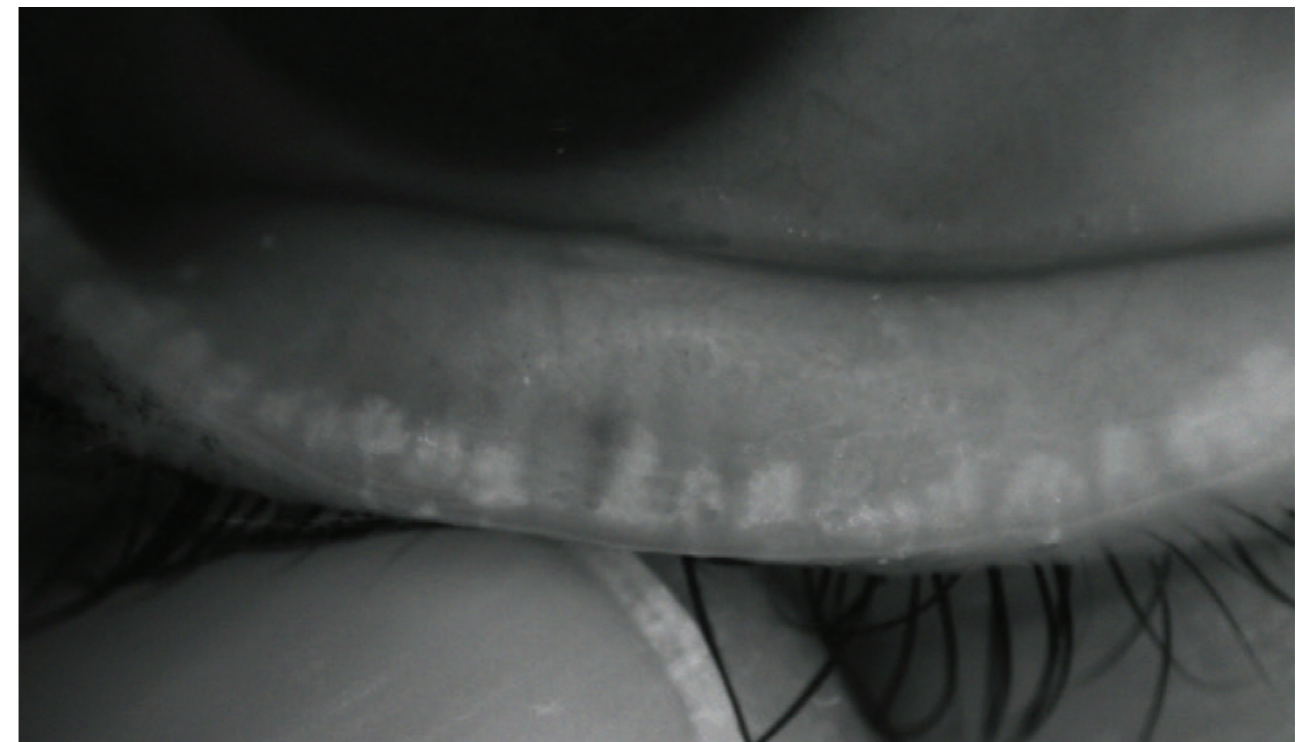
Values

Interferometry: OD 30 nm OS 30-80 nm

NIBUT: OD 7,2 sec, OS 8,1 sec

Tear Meniscus: OD 1mm, OS 0,8mm

Meibography: OD 68% loss, OS 62% loss



Case 8 – Dry Eye due to excessive evaporation

Dr. Luca Vigo

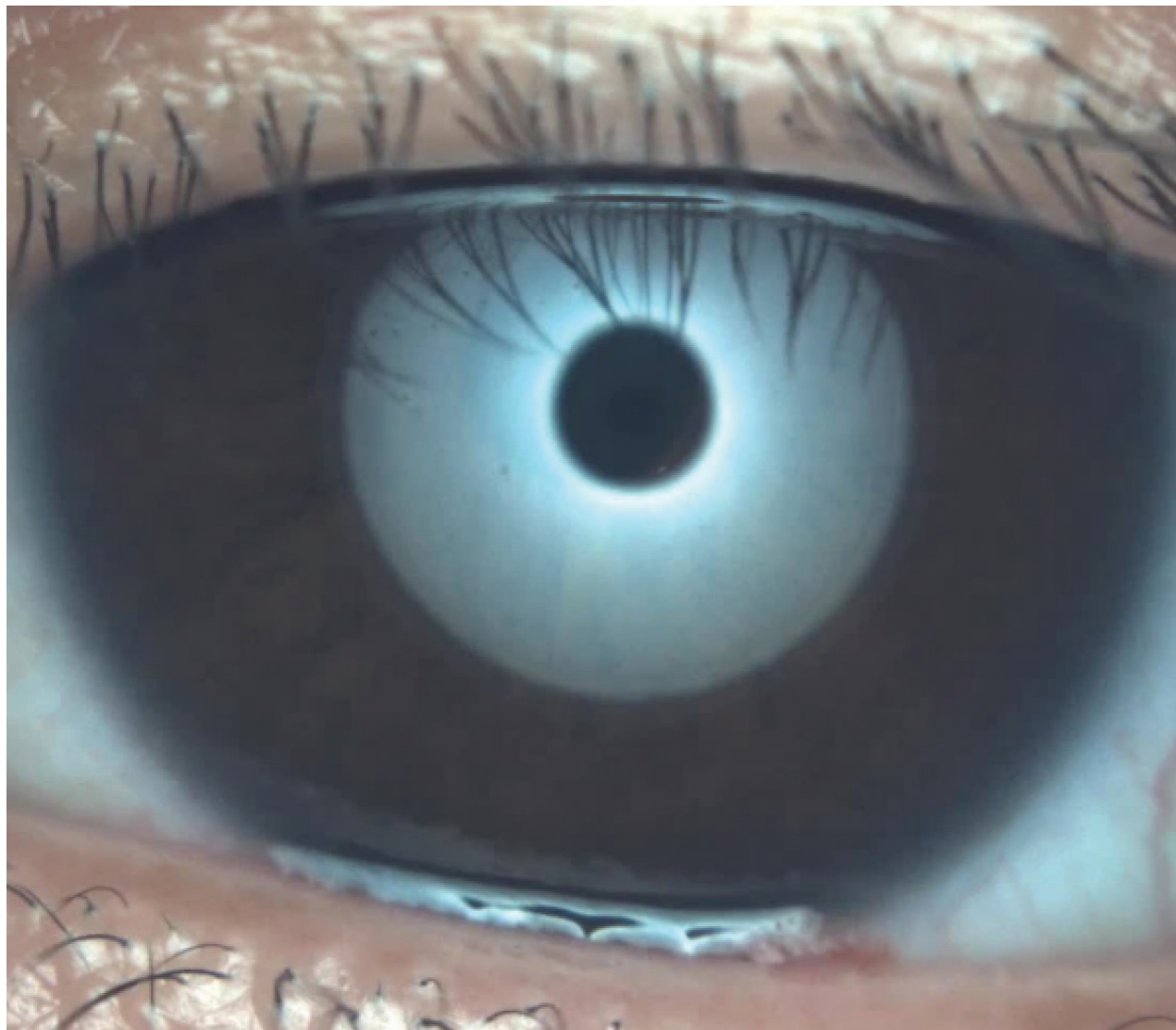Centro Oftalmo Chirurgico Carones
Italy

Patient's description

74-year-old man.
Hyperope and presbyope, uses multifocal lenses. He regularly takes drugs for the prostate but does not report other problems on the digestive and metabolic level.

Dysfunction description

Long-term complaints of red, itchy eyes, with hyper lacrimation and blurred vision, a sensation of a foreign body and sometimes burning and photophobia.
Physical examination: gerontoxon, nuclear cortical cataract in evolution, chronic blepharitis and lower ectropion, major blepharochalasis.



Case 9 – Dry Eye with altered lipid secretion

Dr. Luca Vigo

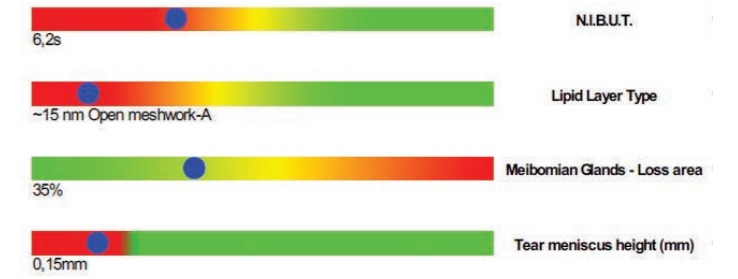
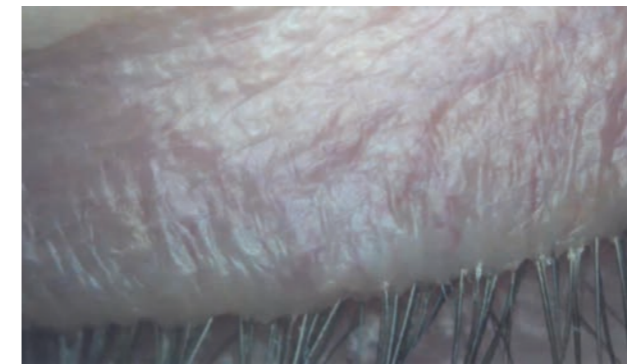Centro Oftalmo Chirurgico Carones
Italy

Patient's description

60-year-old woman with medium-sized myopia.
It has been found autoimmune hypothyroidism for some years for which she is in chronic therapy with eutirox.

Dysfunction description

She cannot use contact lenses and complains about dryness when waking up and during the day. Reports redness in the eyes, burning and sensation of a foreign body, photophobia and difficulty in night driving.
Objective examination: bilateral important blepharochalasis with moderate irritation of the palpebral edge of the chronic type.
Marked conjunctival hyperaemia and suffering of corneal epithelium especially in the inferior paracentral area. Grade 3 conjunctival corneal and conjunctival staining.



Exams comments

The patient is affected by an important form of Dry Eye for an altered lipid secretion (dysfunction of the Meibomian glands due to the important blepharochalasis) and a scarce production of aqueous component by the lacrimal gland (consequent to hypothyroidism). The suggested therapy consists in the use of cyclic hydrocortisone, tear substitutes based on hyaluronic acid or carboxymethyl cellulose with high molecular weight or high concentration and stimulation of the Meibomian glands with pulsed light and of the lacrimal gland with radiofrequency.

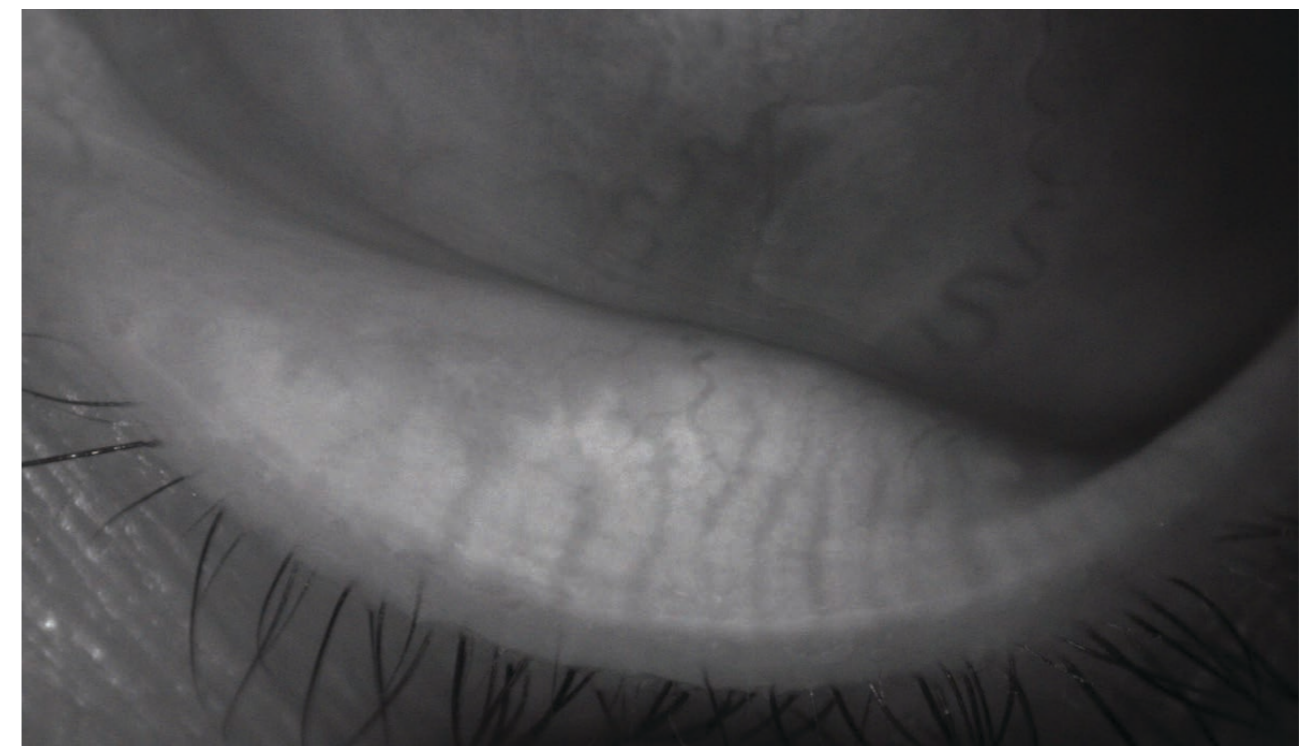
Values

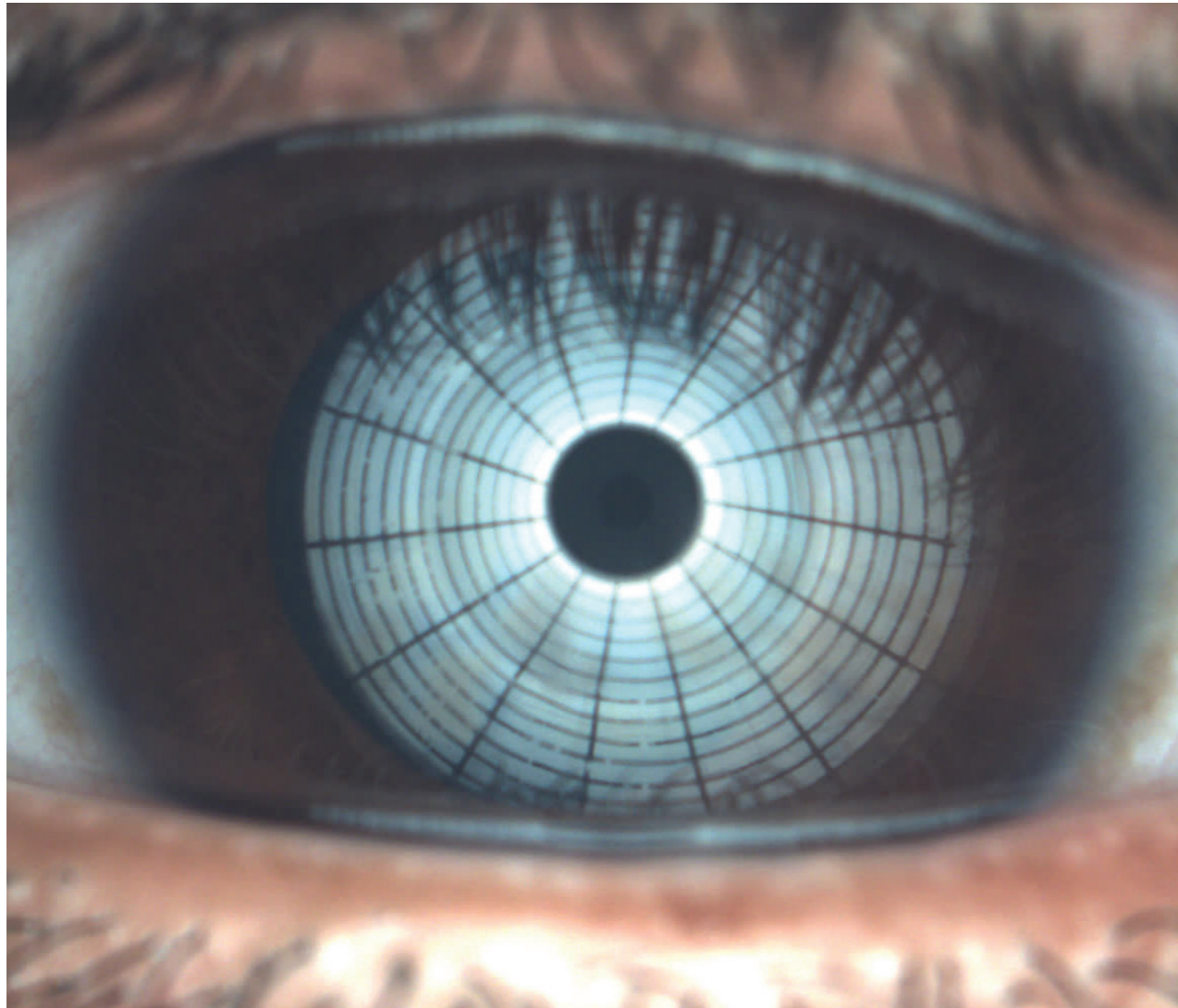
Interferometry: OD. 15nm, OS: 30nm

Tear Meniscus: OD 0.1 mm, OS: 0.15 mm

NIBUT: OD 6.5 sec, OS: 7.2 sec

Meibography: OD: 35% loss, OS 40% loss





Case 10 – Evaporative Dry Eyes

Dr. Sri Ganesh
Nethradhama Super Speciality Eye Hospital
Bengaluru
India

Patient Description

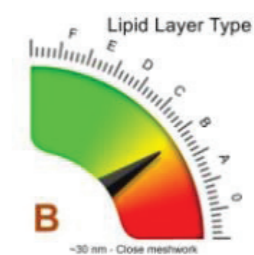
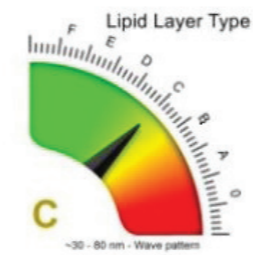
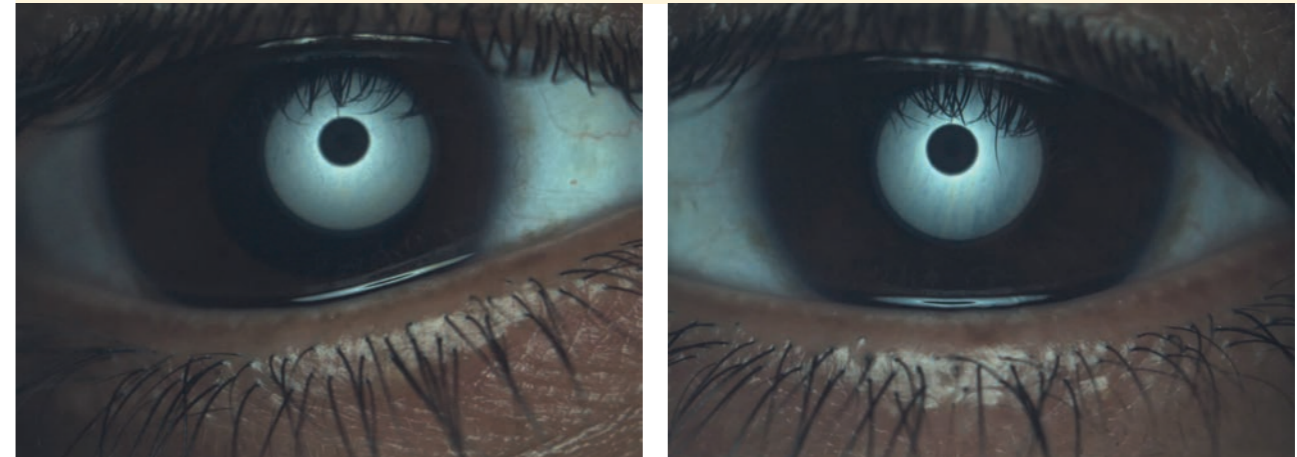Patient aged 35 y/ male reported to our clinic complaining of itching and dryness in both eyes and was interested in refractive surgery. Previous history indicated the patient being Soft contact lens user. The reported VA for Both Eyes were 6/6 and N5

Values OD
Interferometry: >30nm
Tear meniscus: 0.17mm
NIBUT: 5.4Sec
Meibography: 11 % Area Loss

Values OS
Interferometry: <30nm
Tear meniscus: 0.24mm
NIBUT: 4.4Sec
Meibography: 10% Area Loss

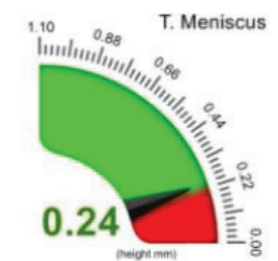
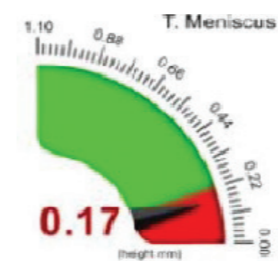
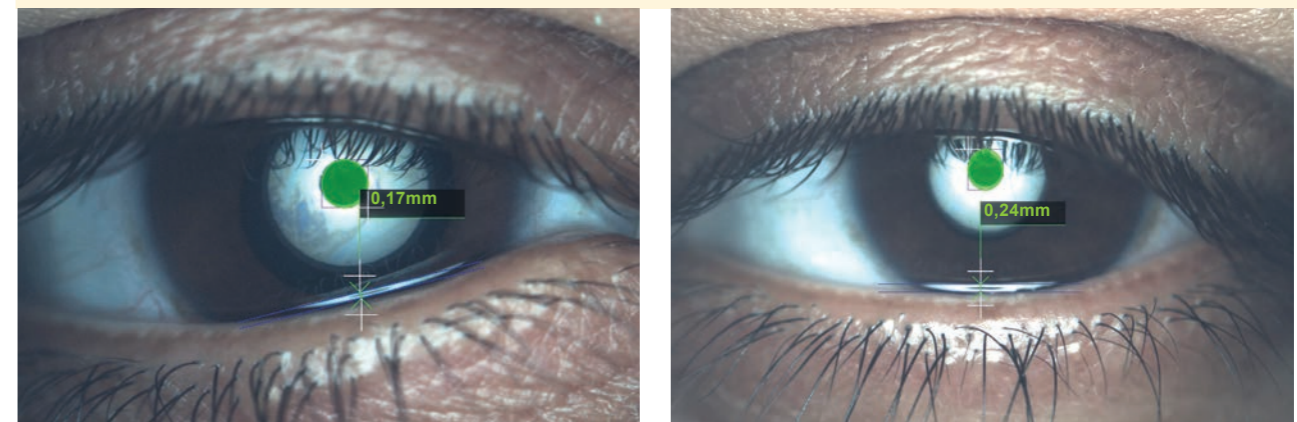
Lipid Layer Analysis

The Lipid analysis was good for both eyes with values less than <30nm



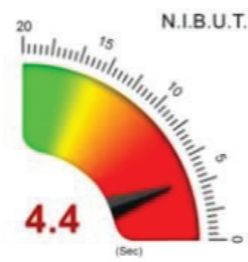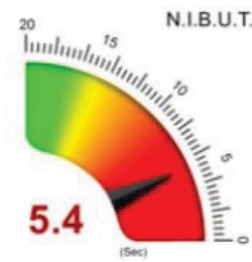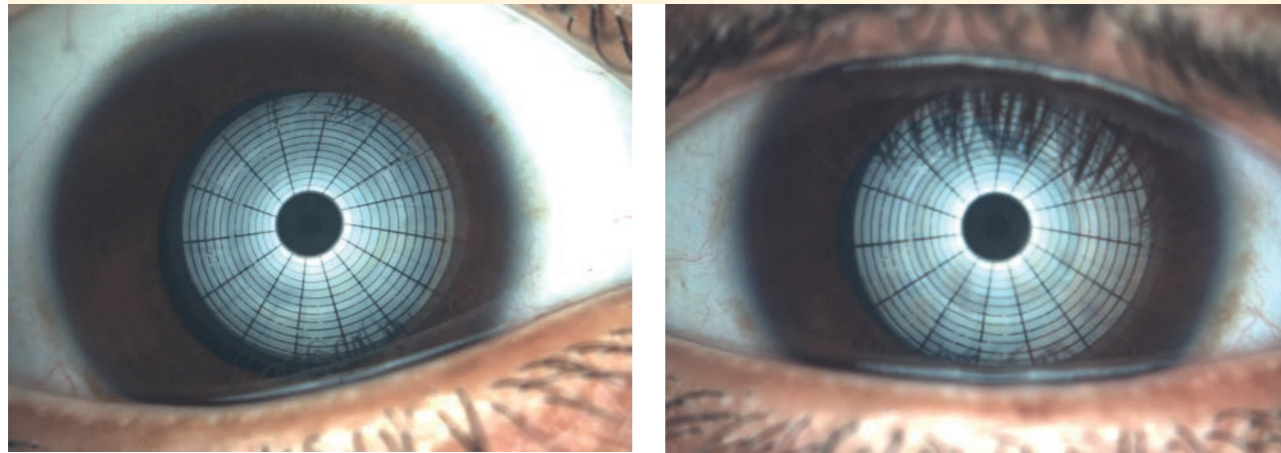
Tear Meniscus

The Ocular surface analyser showed less tear meniscus height for OD eye with 0.17mm with normal height for the OS eye at 0.24mm



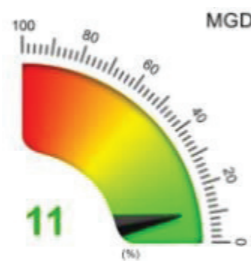
NIBUT Graph

The average NIBUT value reported for OD eye was 5.4 and for OS eye was 4.4 sec



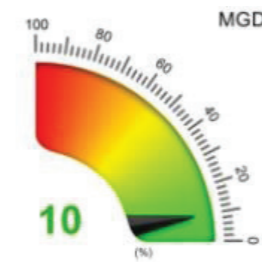
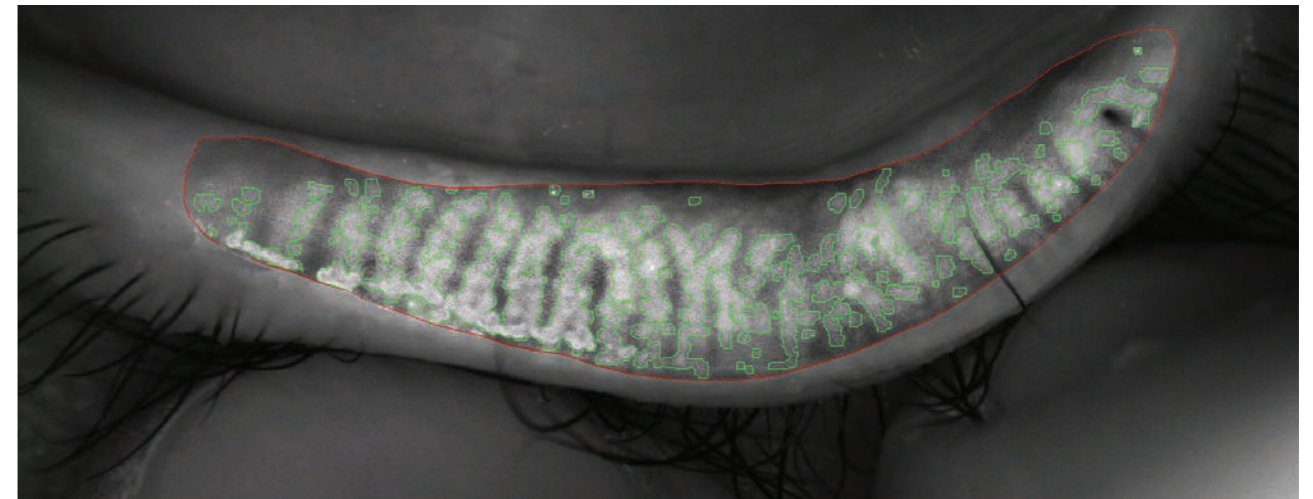
MGD

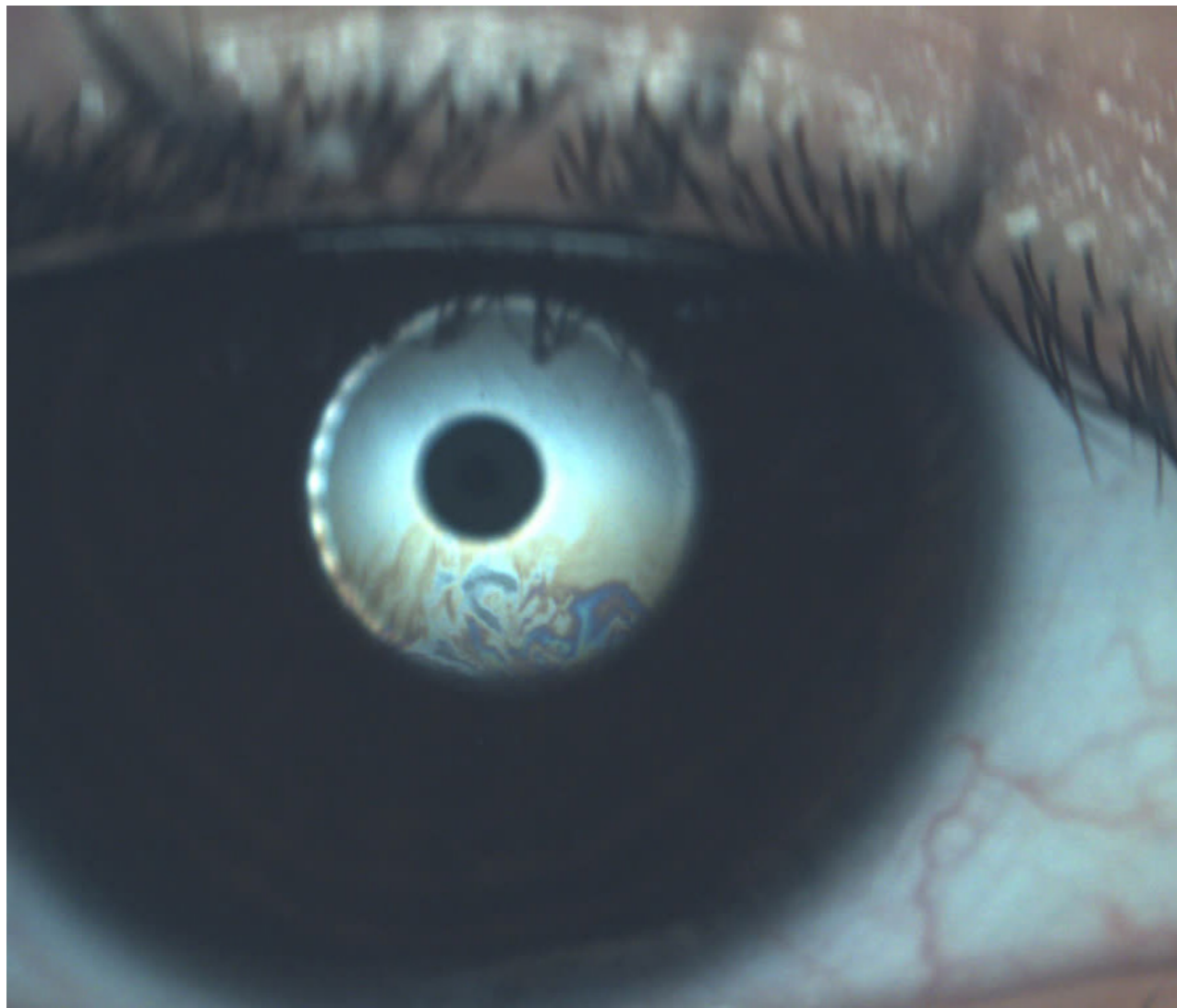
The mgd analysis showed minimal loss of 10% and 11% for both eye



Conclusion

- TBUT was performed for both eye in same patient and was reported at 5sec which corresponds with the values of NIBUT from OSA.
- The patient is advised for treatment with lubricants and IPL (intense pulse light) following above investigations prior to Lasik.
- Patient is diagnosed to have evaporative dry eye.





Case 11 – Post Lasik Severe Dry Eye

Dr. Sri Ganesh
Nethradhama Super Speciality Eye Hospital
Bengaluru
India

Patient Description

Patient aged about 26yrs female reported in our clinic complaining of redness ,irritation, intolerance to light, burning sensation and watery in BE.
On Slit lamp examination cornea showed moderate staining, severe MGD, unhealthy tear film.

Values OD

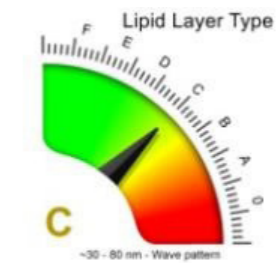
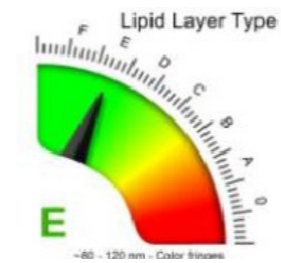
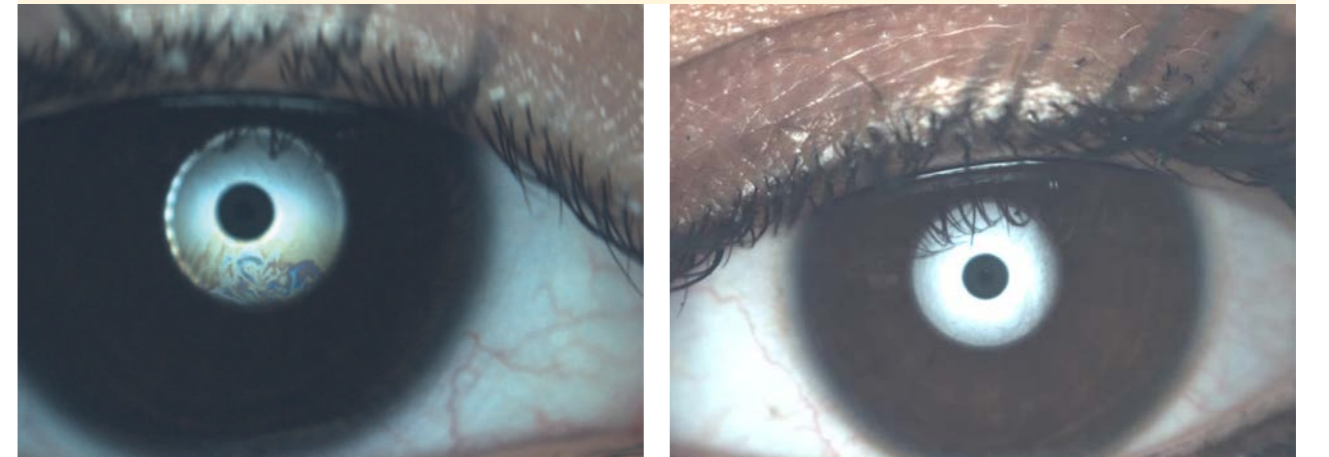
Interferometry: >80nm
Tear meniscus: 0.21mm
NIBUT: 11.2Sec
Meibography: 32 % Area Loss

Values OS

Interferometry: >80nm
Tear meniscus: 0.27mm
NIBUT: 8.8Sec
Meibography: 20 % Area Loss

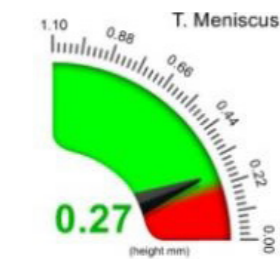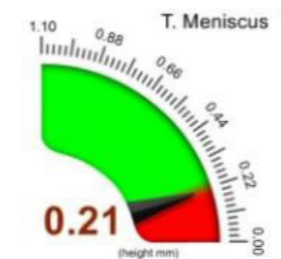
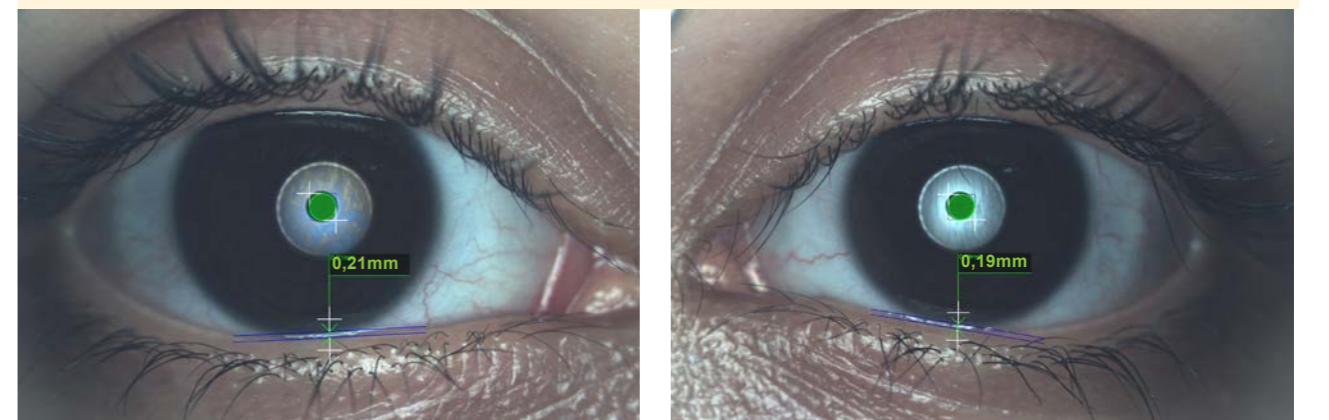
Lipid Layer Analysis

The Lipid analysis was good for both eyes with values greater than >80nm for both eyes



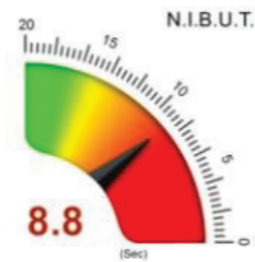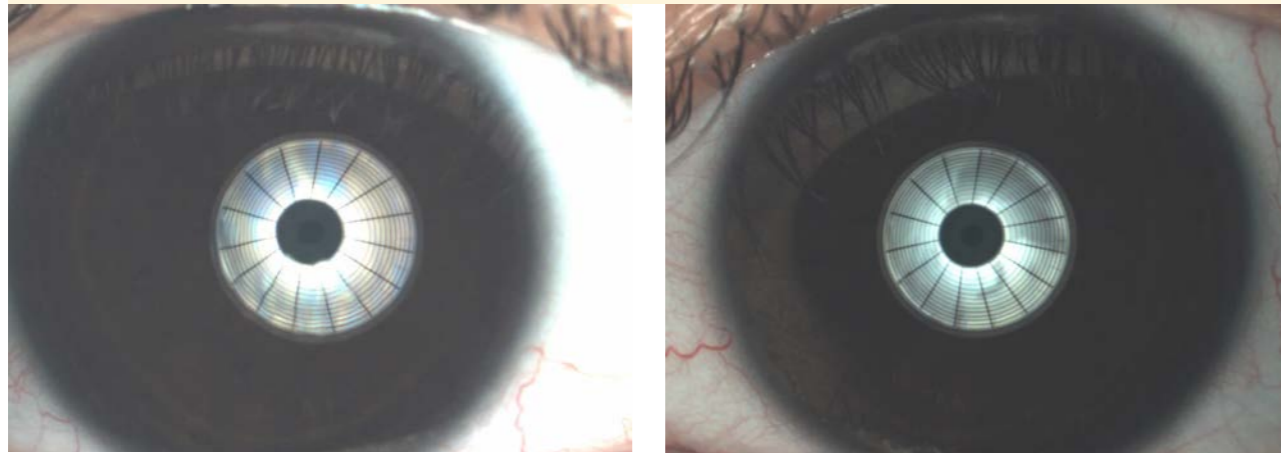
Tear Meniscus

The Ocular surface analyser showed normal tear meniscus height for OD eye with 0.21 mm with normal height for the OS eye at 0.27mm



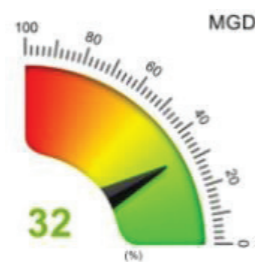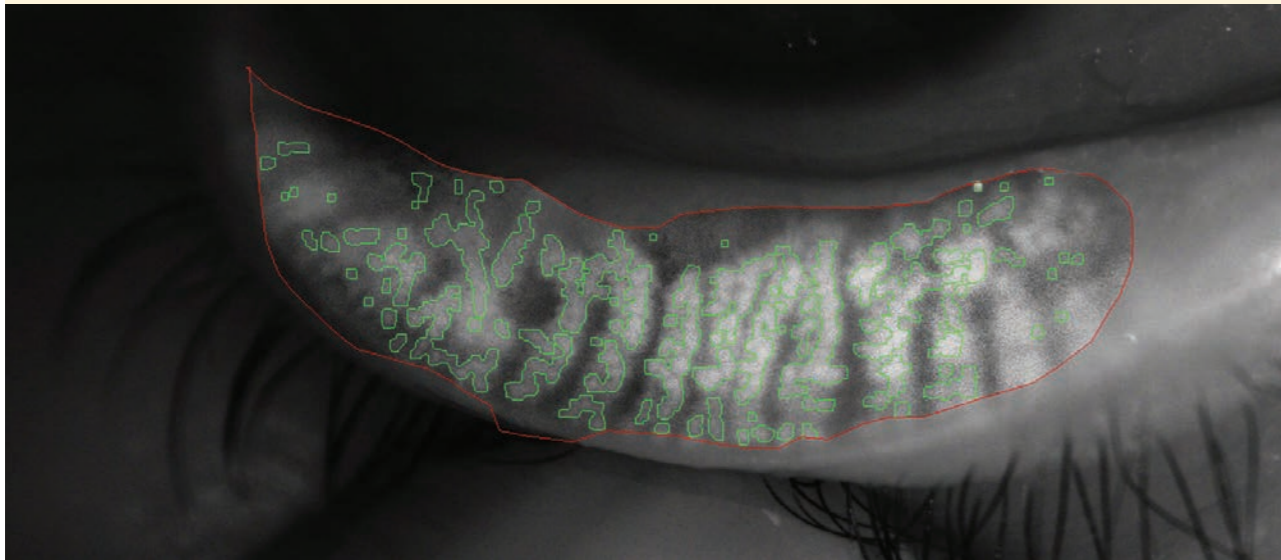
NIBUT Graph

The average NIBUT value reported for OD eye was 11.2 sec and for OS eye was 8.8 sec



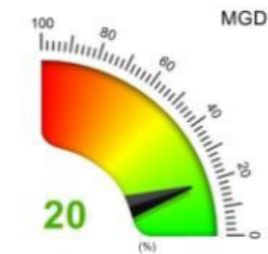
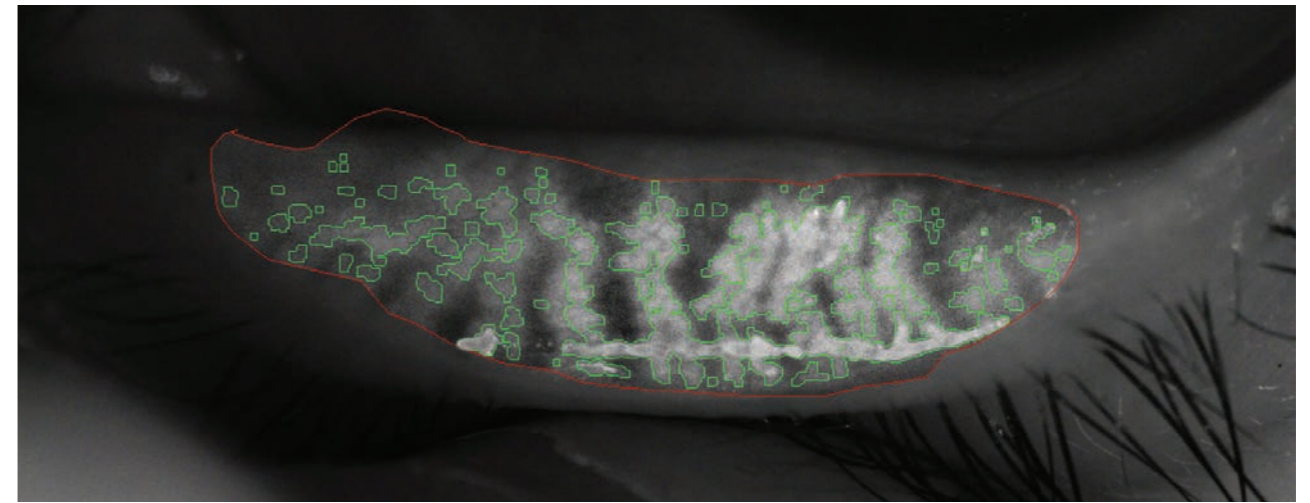
MGD

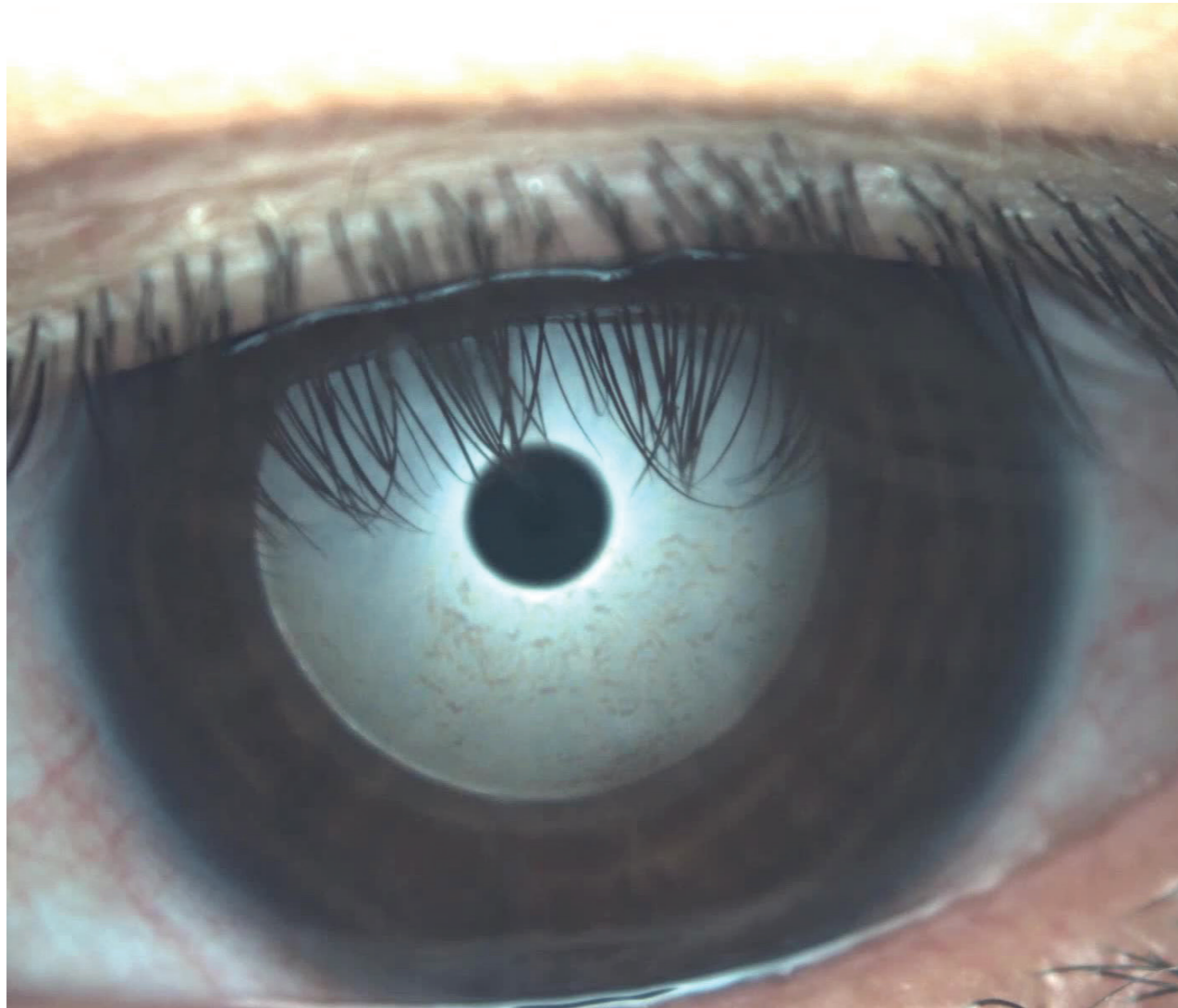
The mgd analysis showed loss of 32% for OD eye and 20% for OS eye



Conclusion

- The patient was treated with IPL and lubricants for 3 sittings
- After 2nd sitting of IPL NIBUT RE was 4.2 mgd dropout area was 22%
- Patient symptomatically improved by 40%
- The above OSA findings are after 3rd IPL Sitting ,where in the patient had improved by 60% with improvement in Lipid layer and NIBUT.





Case 12 – Dry Eye

Dr. Sri Ganesh

Nethradhama Super Speciality Eye Hospital
Bengaluru
India

Patient Description

Patient Aged about 38 years Male reported to our clinic complaining of Irritation and dryness in both eye. Best corrected VA for OD was 6/6 and N6 and OS was 6/6 and N6.

On slit lamp evaluation Both Eye showed allergy, frothy discharge indicating mgd and few blocked meibomian gland.

Values OD

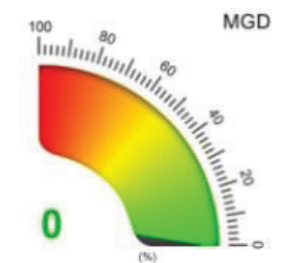
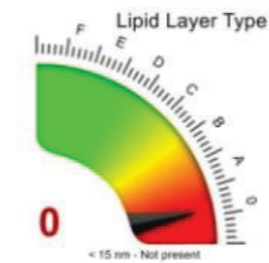
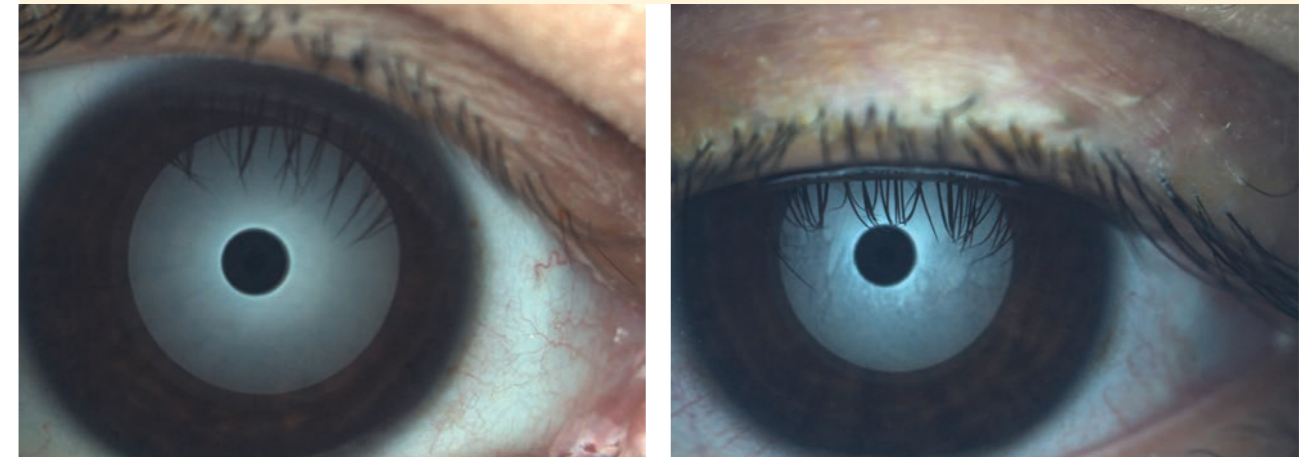
Interferometry: <15nm
Tear meniscus: 0.22
NIBUT: 18.5Sec
Meibography: 22%Loss area

Values OS

Interferometry: <15nm
Tear meniscus: 0.26
NIBUT: 16.9Sec
Meibography: 0%Loss area

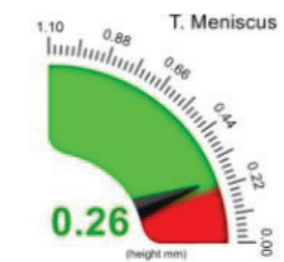
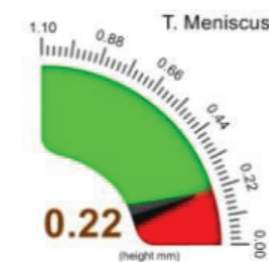
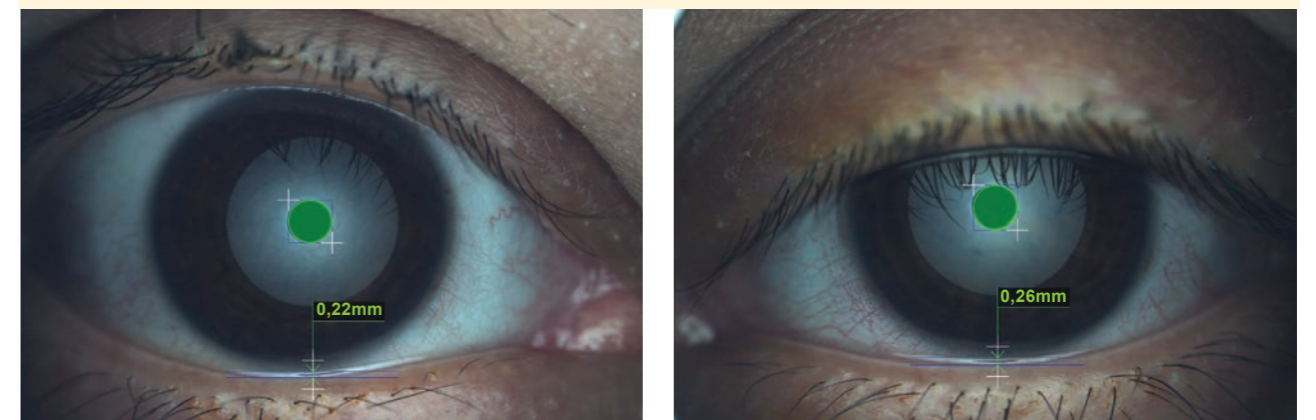
Lipid Layer Analysis

The Lipid analysis was very poor for both eyes with values less than <15nm



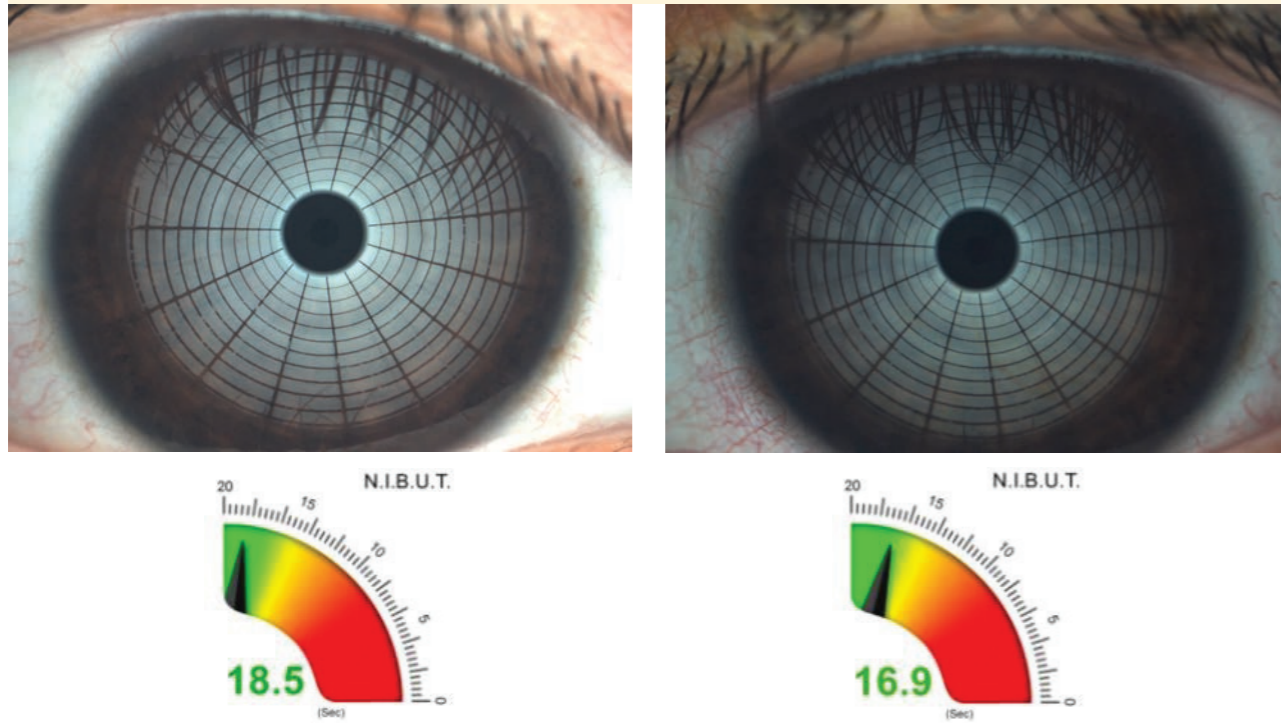
Tear Meniscus

The Ocular surface analyser showed less tear meniscus height for OD eye with 0.22mm with normal height for the OS eye at 0.26mm



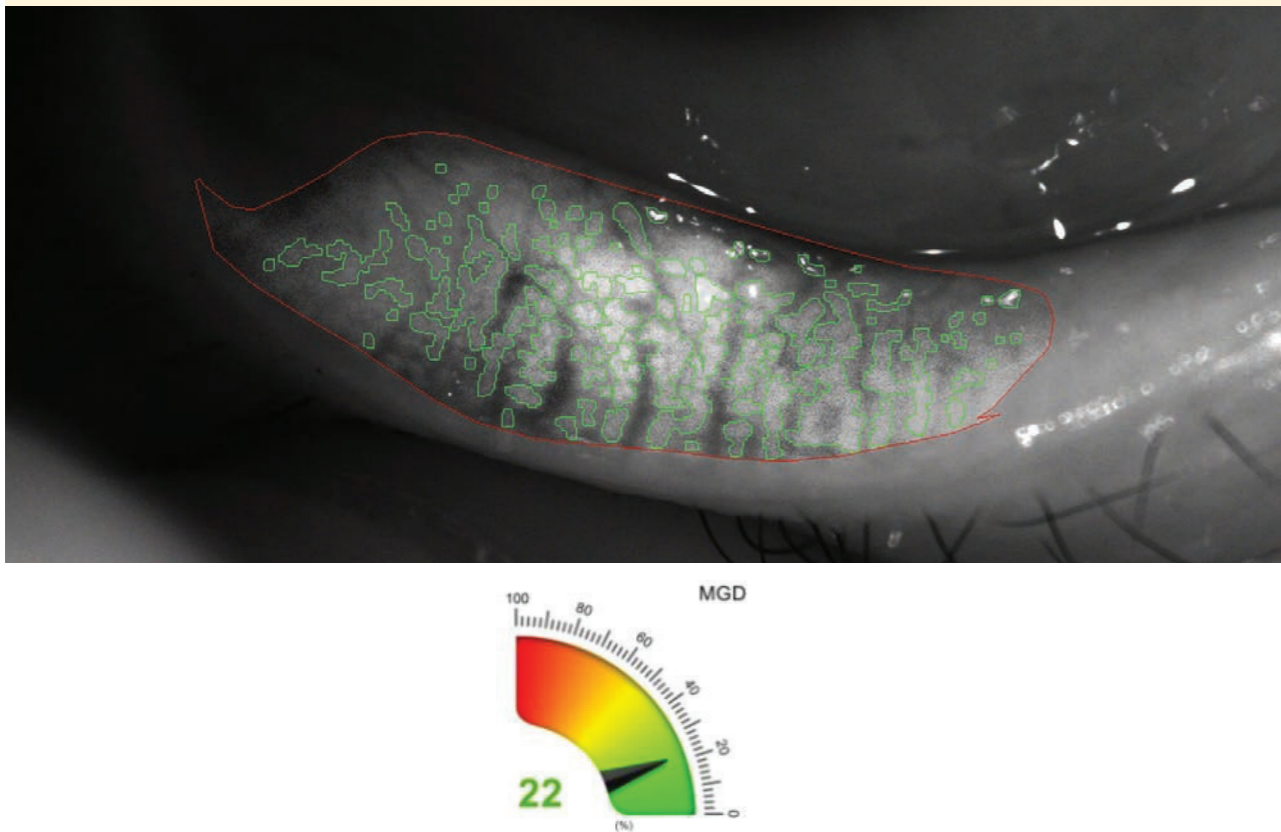
NIBUT Graph

The average NIBUT value reported for OD eye was 18.5sec and for OS eye was 16.9sec



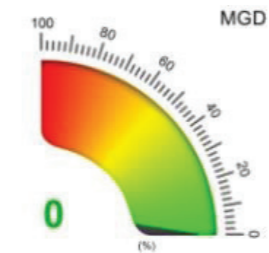
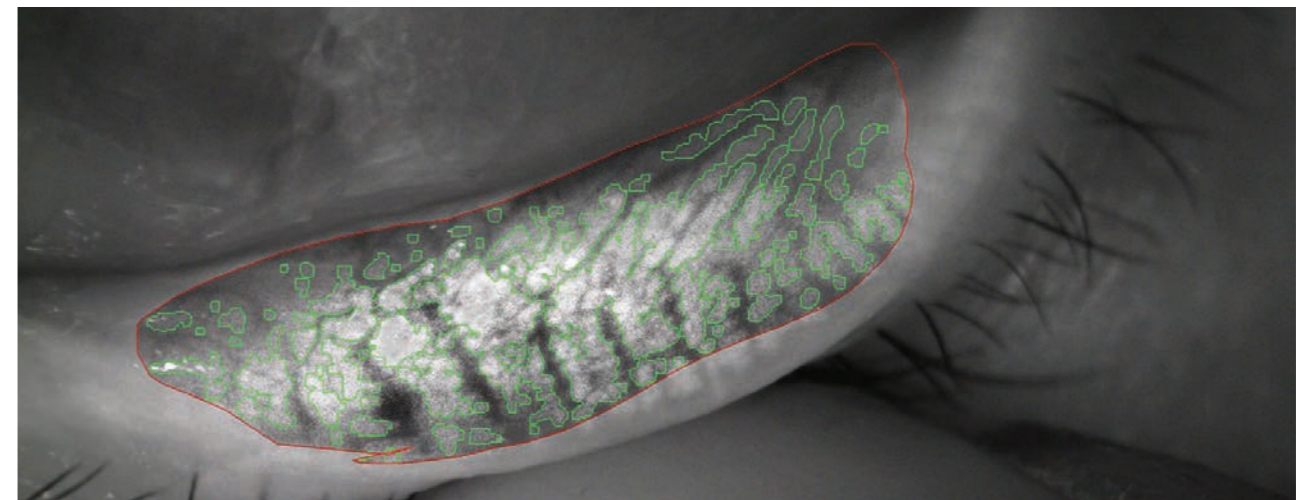
MGD

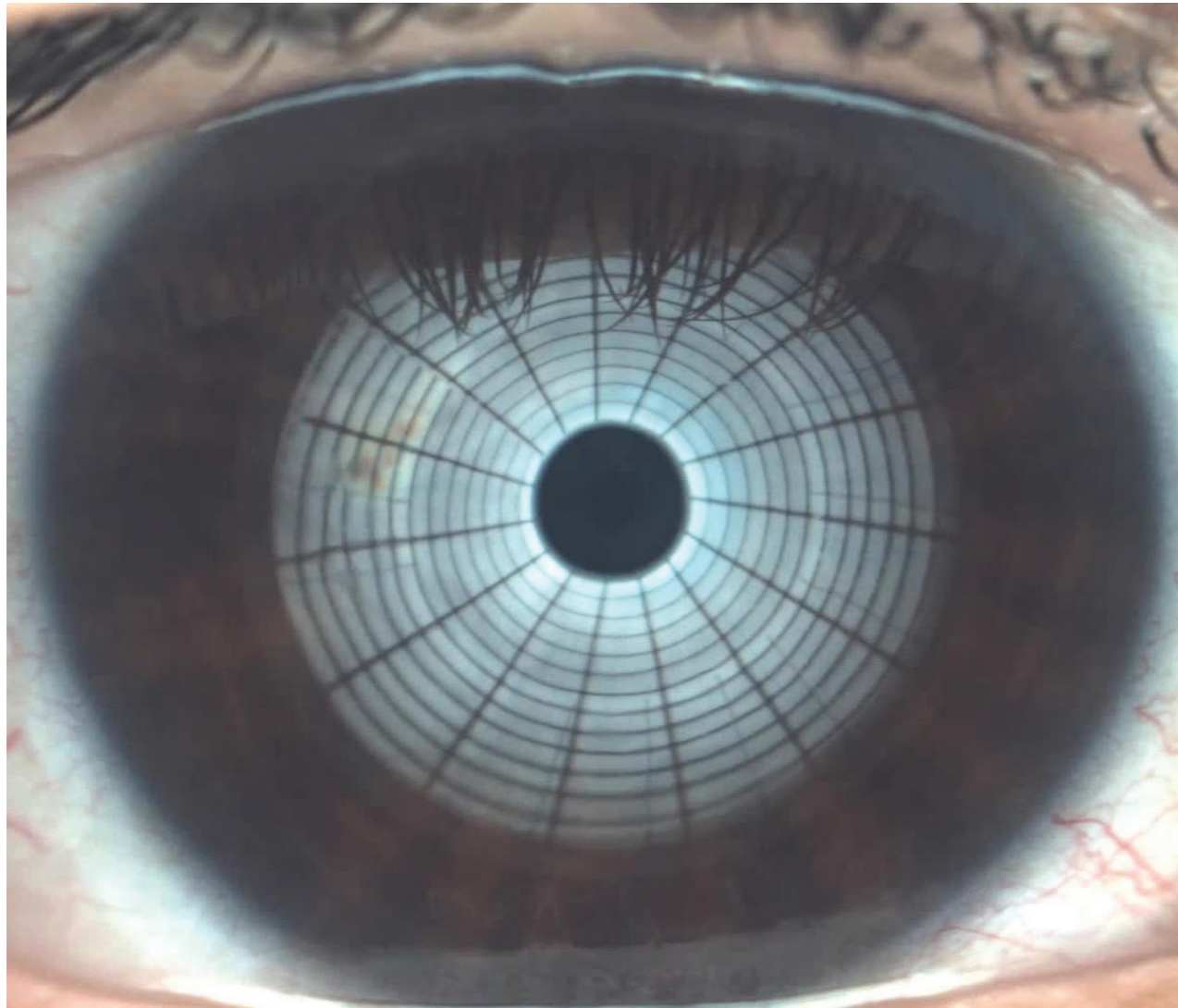The mgd analysis showed minimal loss of 22% for OD and 0% for OS eyes



Conclusion

- The patient was treated with IPL post which the TBUT has improved.
- The NIBUT result showed break up at 17 sec. TBUT before IPL was recorded at 5 sec.
- The OSA results confirmed of poor Meibomian glands with loss of 22 % for OD.
- The patient was treated for IPL 3 sittings and with lubricants the patient has significant improvement in the conditions.





Case 13 – Post Presbyopic Lasik

Dr. Sri Ganesh
Nethradhama Super Speciality Eye Hospital
Bengaluru
India

Patient Description

Female Patient aged 48 yrs reported to us of dryness in both Eye after prebyopic lasik. Slit lamp corneal evaluation showed normal cornea and flaps well apposed. Best Corrected Visual Acuty was 6/6 and N6 for Both eyes.

Values OD

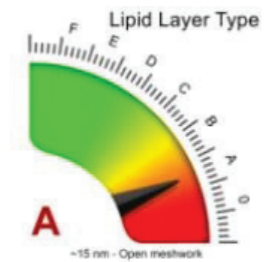
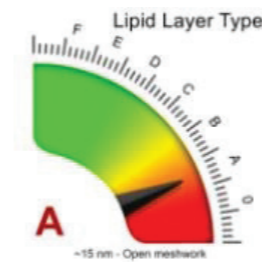
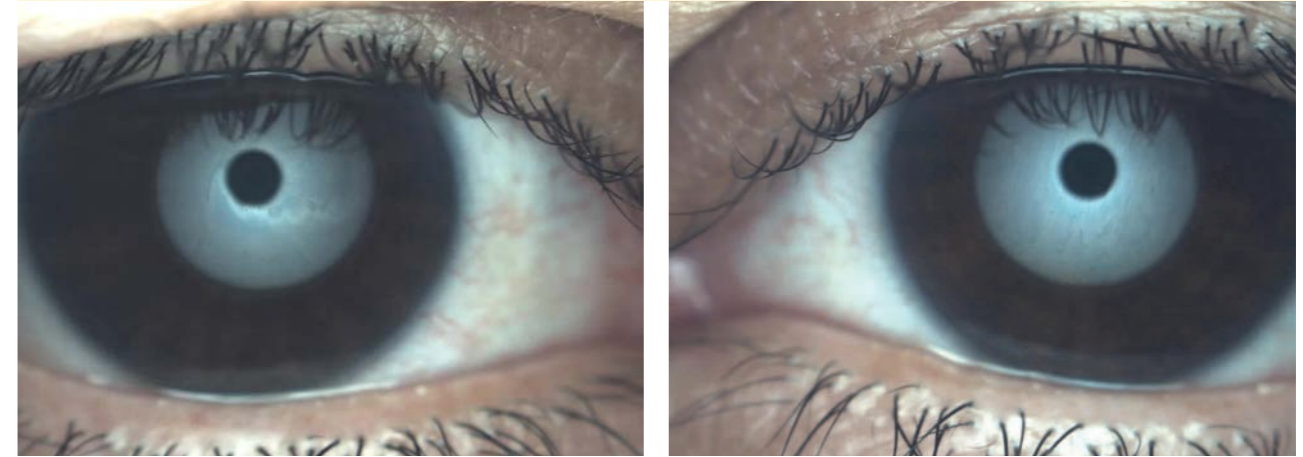
Interferometry: <15nm
Tear meniscus: 0.22mm
NIBUT: 12.0Sec
Meibography: 40 % Area Loss

Values OS

Interferometry: <15nm
Tear meniscus: 0.22mm
NIBUT: 14.8Sec
Meibography: 42 % Area Loss

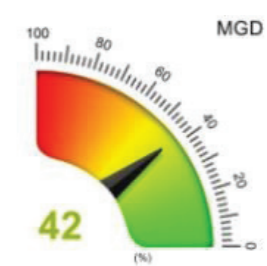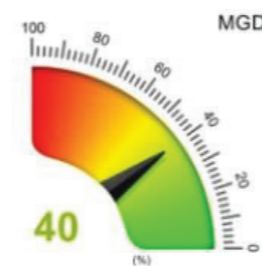
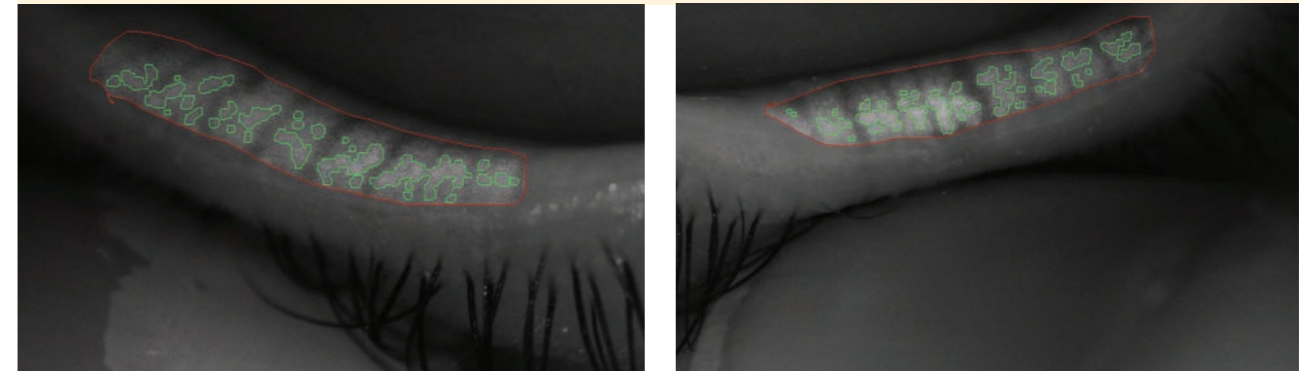
Lipid Layer Analysis

The Lipid analysis was poor for both eyes with values less than <15nm



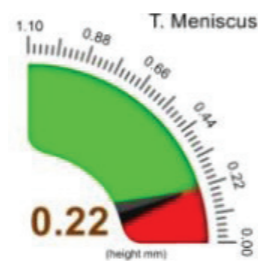
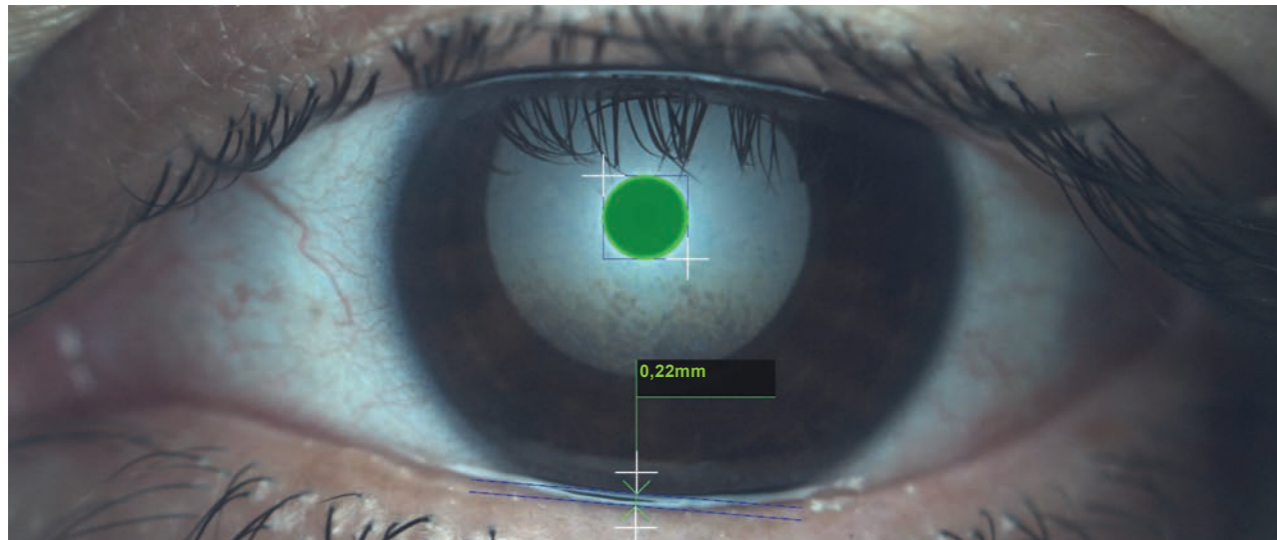
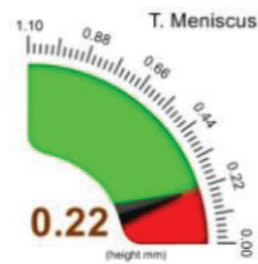
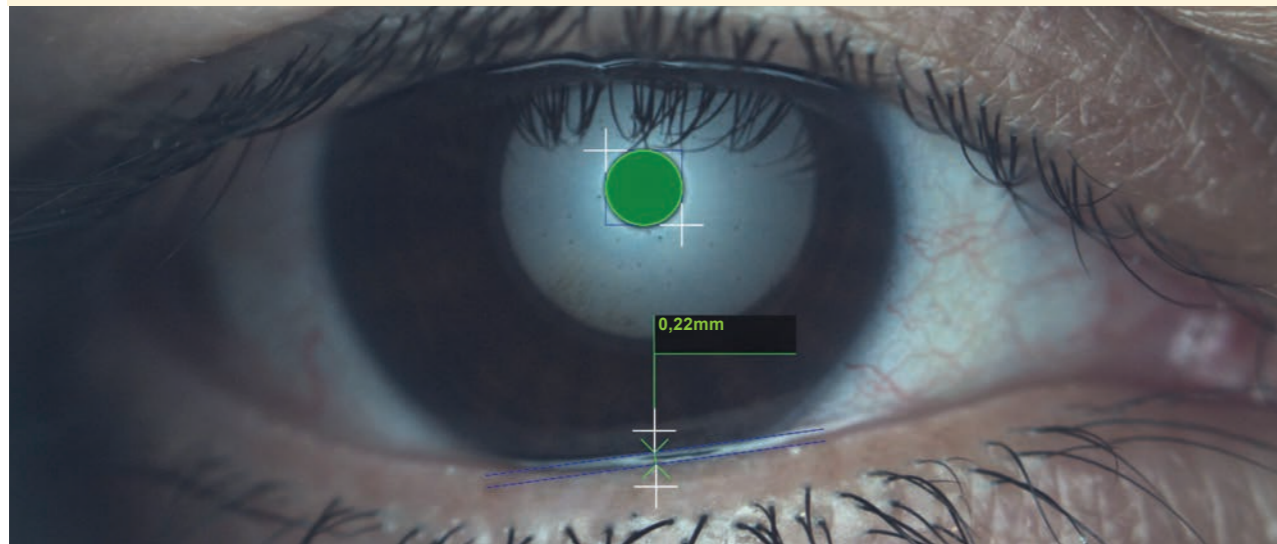
MGD

The mgd analysis showed minimal loss of 40% for OD and 42 % for OS



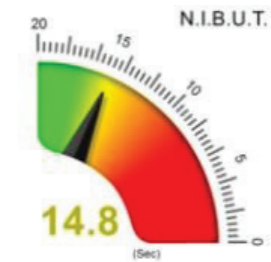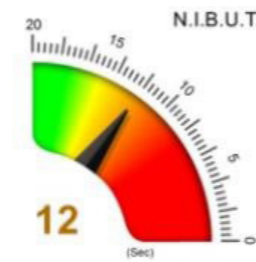
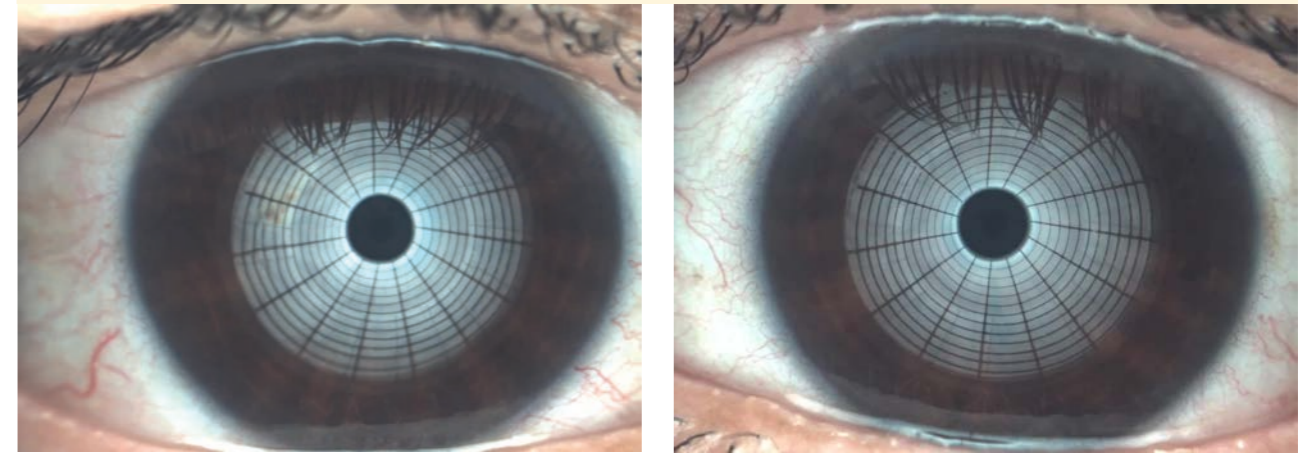
Tear Minuscus

The Ocular surface analyser showed normal tear meniscus height for OD eye with 0.22 mm and normal height for OS eye at 0.22 mm



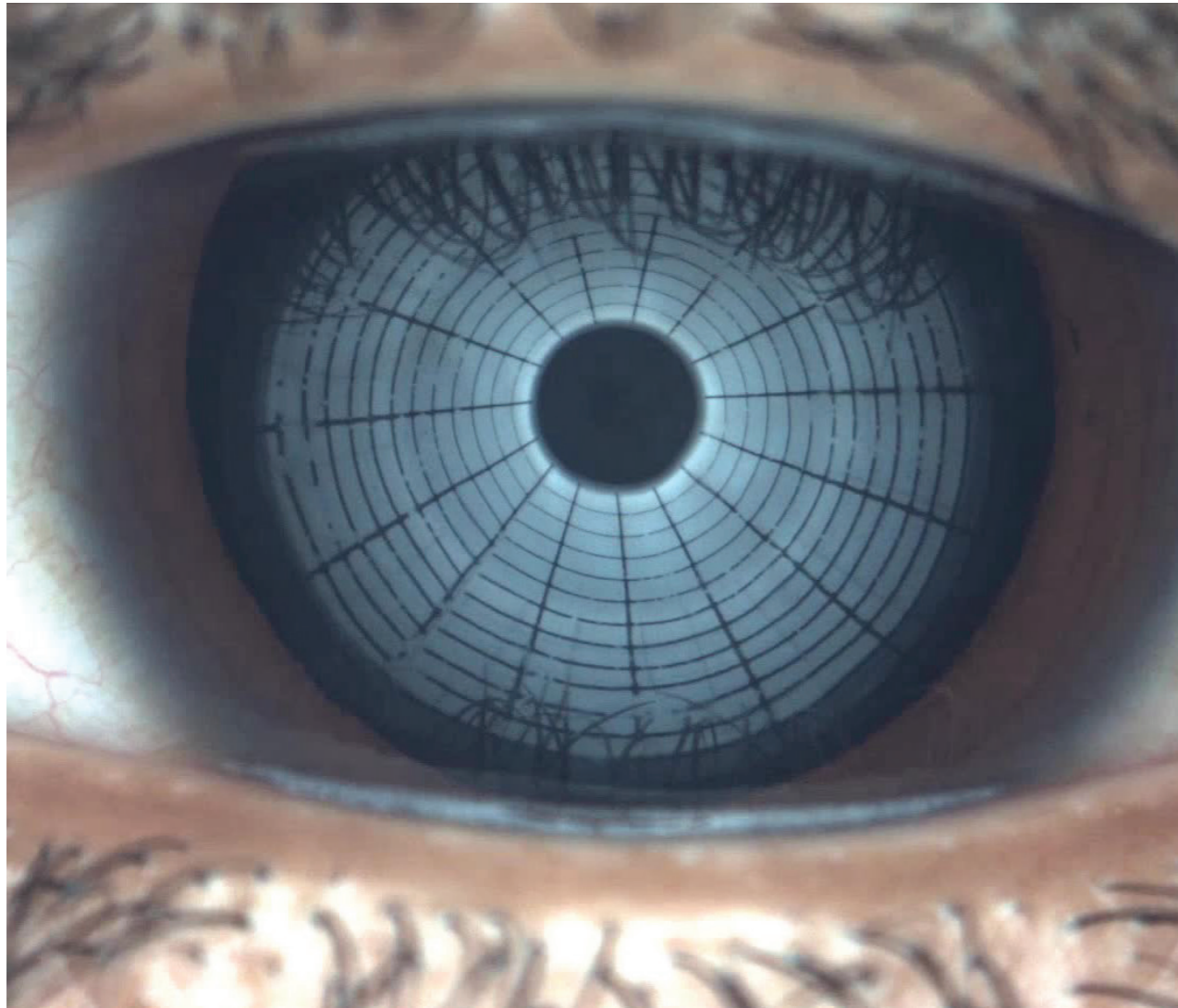
NIBUT Graph

The average NIBUT value reported for OD eye was 12.0 and for OS eye was 14.8 sec



Conclusion

- The OSA showed less Lipid layer
- The MGD test showed loss of 42 % with blocked glands
- The patients was diagnosed to have loss of mgd with evaporative dry eye



Case 14 – Evaporative Dry Eye

Dr. Sri Ganesh
Nethradhama Super Speciality Eye Hospital
Bengaluru
India

Patient Description

Female patient aged about 33 years complains of dry eyes and eye strain for 1 year patient is computer user (upto about 9 hrs /day) On slit lamp examination Mild corneal staining seen with blocked meibomian glands

Values OD

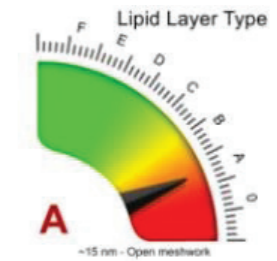
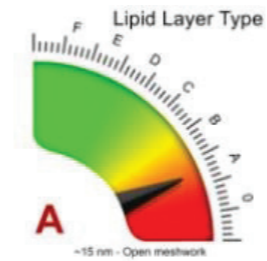
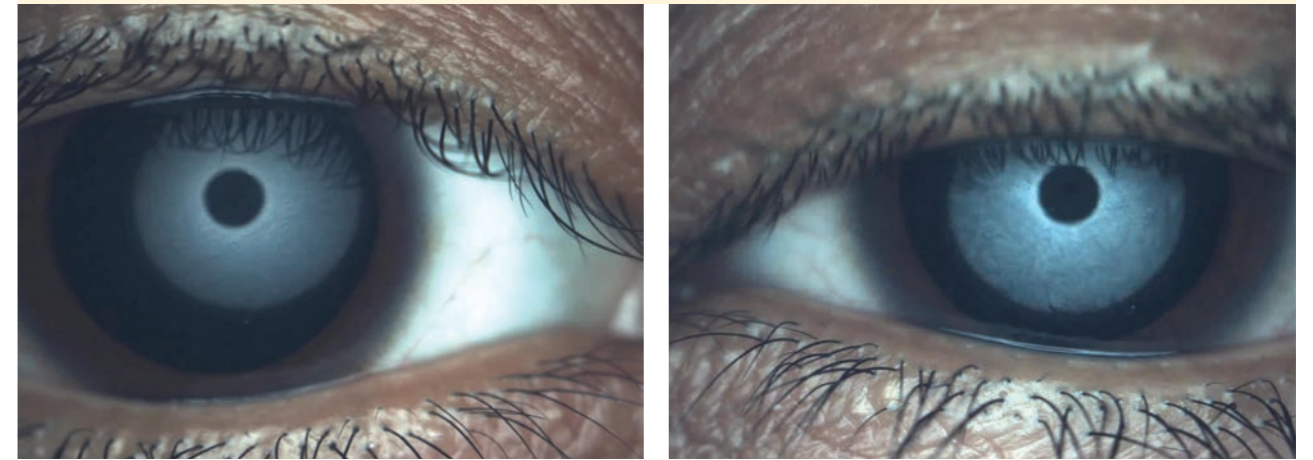
Interferometry: <15nm
Tear meniscus: 0.17mm
NIBUT: 6.1 Sec
Meibography: 49% Loss area

Values OS

Interferometry: <15nm
Tear meniscus: 0.18mm
NIBUT: 6.9 Sec
Meibography: 30% Loss are

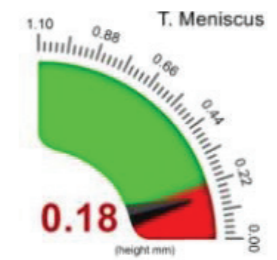
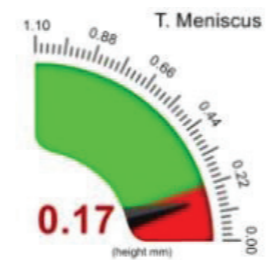
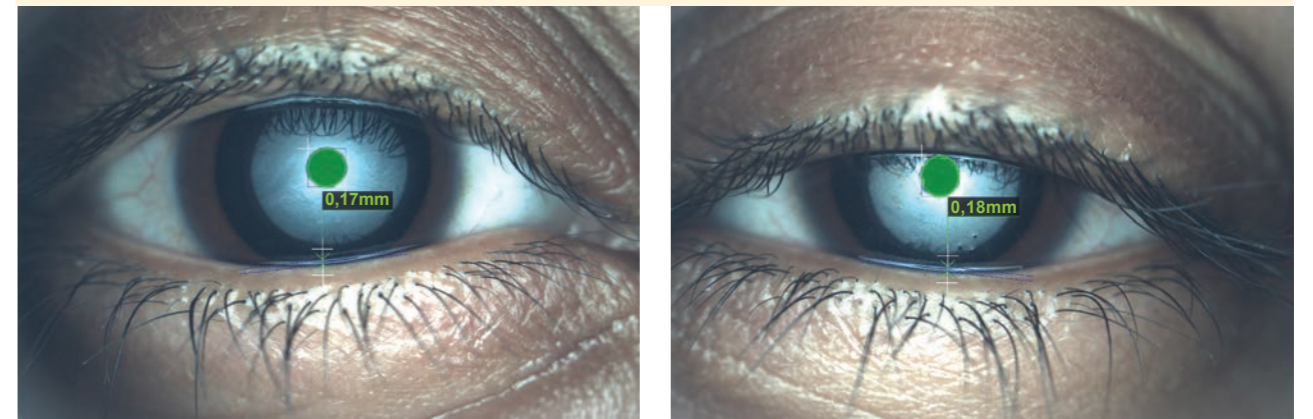
Lipid Layer Analysis

The Lipid analysis was very poor for both eyes with values less than <15nm



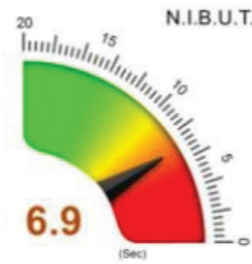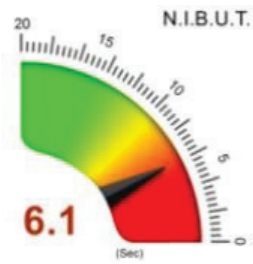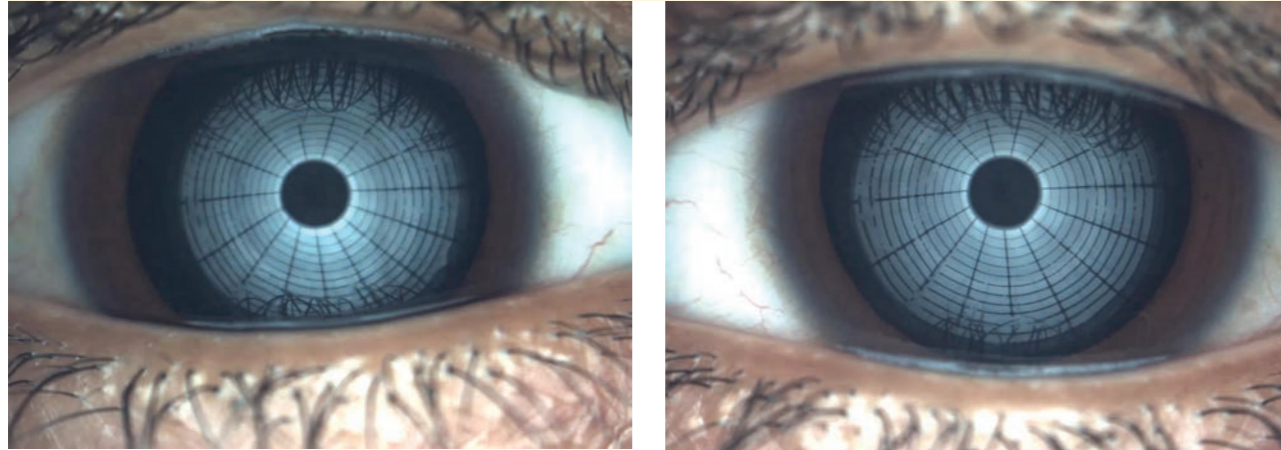
Tear Meniscus

The Ocular surface analyser showed less tear meniscus height for OD eye with 0.17 mm and the OS eye at 0.18mm



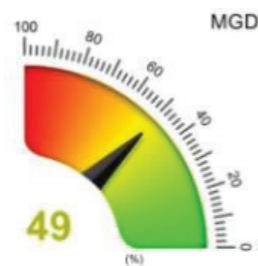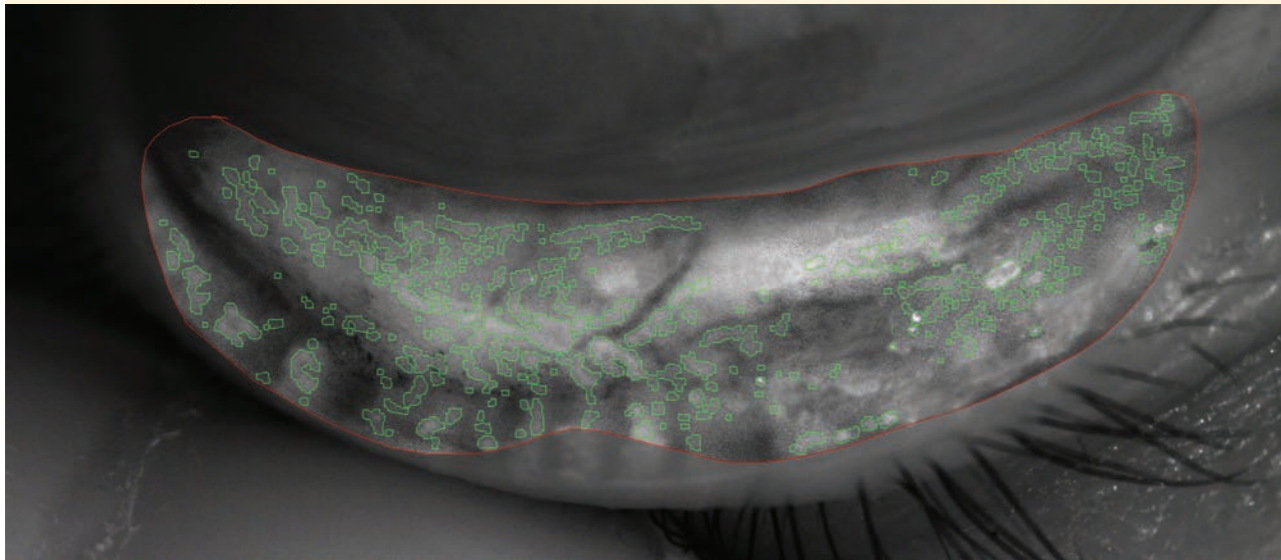
NIBUT Graph

The average NIBUT value for OD eye was 6.1 sec and for OS eye was 6.9 Sec which is less than the normal breakup time.



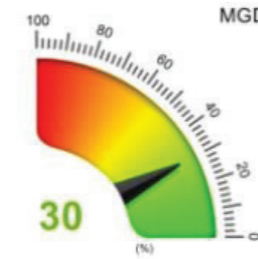
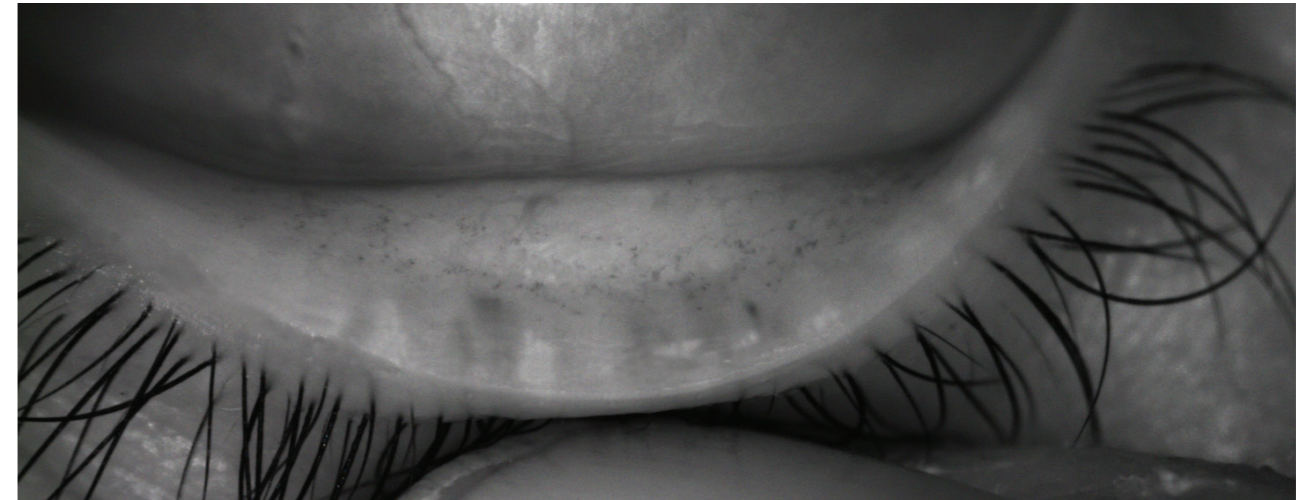MGD

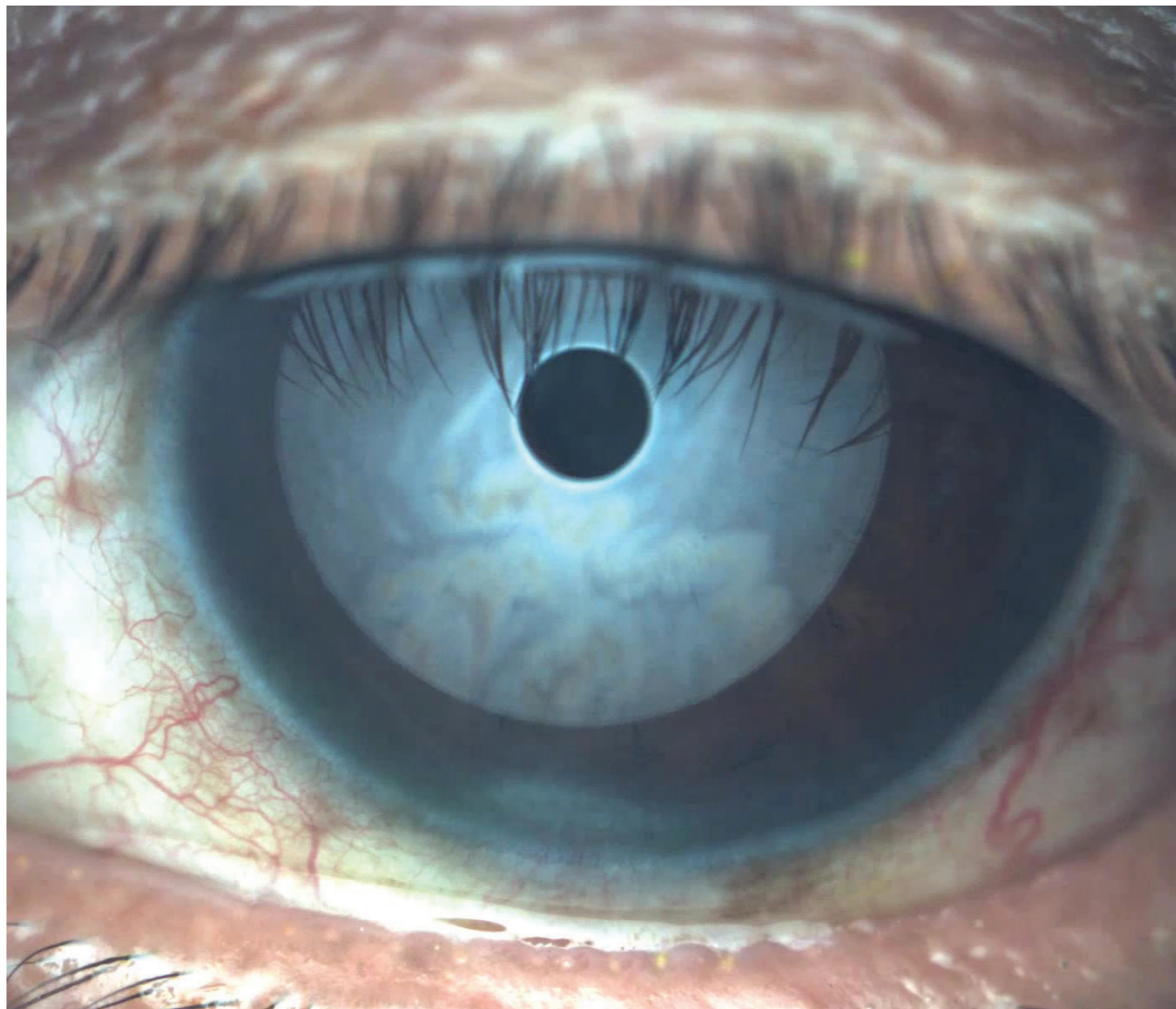
The mgd analysis showed loss of 49% for OD and 30% for OS eyes



Conclusion

- Both Eye are diagnosed as evaporative dry eyes
- The OSA confirms of loss in MGD area.





Case 15 – Severe Dry Eye

Dr. Sri Ganesh
Nethradhama Super Speciality Eye Hospital
Bengaluru
India

Patient Description

Patient aged 70 years old complaining of watery and itching in both eyes. On slitlamp evaluation diagnosed as MGD with thick tooth paste like meibum secretion and blocked glands.

Values OD

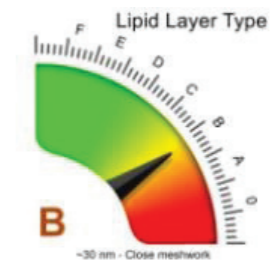
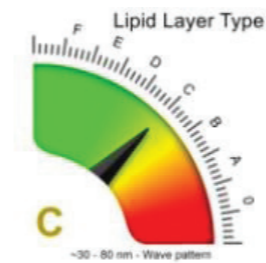
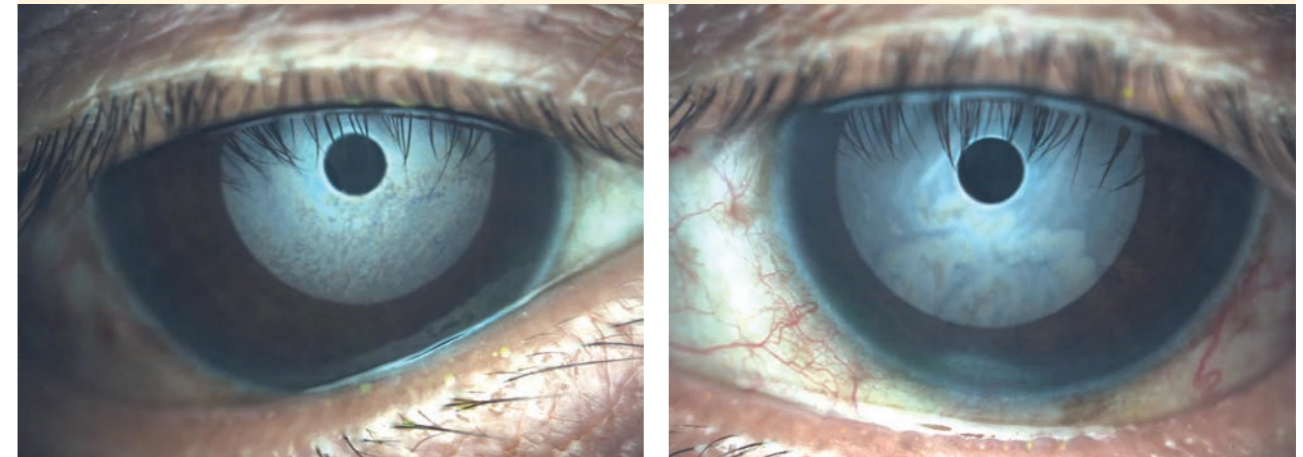
Interferometry: >80nm
Tear meniscus: 0.22mm
NIBUT: 10.85 ec
Meibography: 29 % Area Loss

Values OS

Interferometry: >30nm
Tear meniscus: 0.16mm
NIBUT: 11.0 Sec
Meibography: 27 % Area Loss

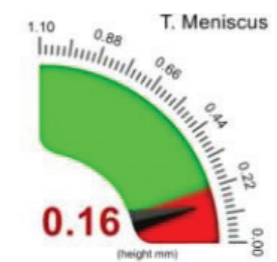
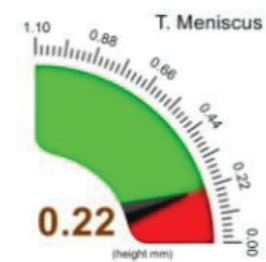
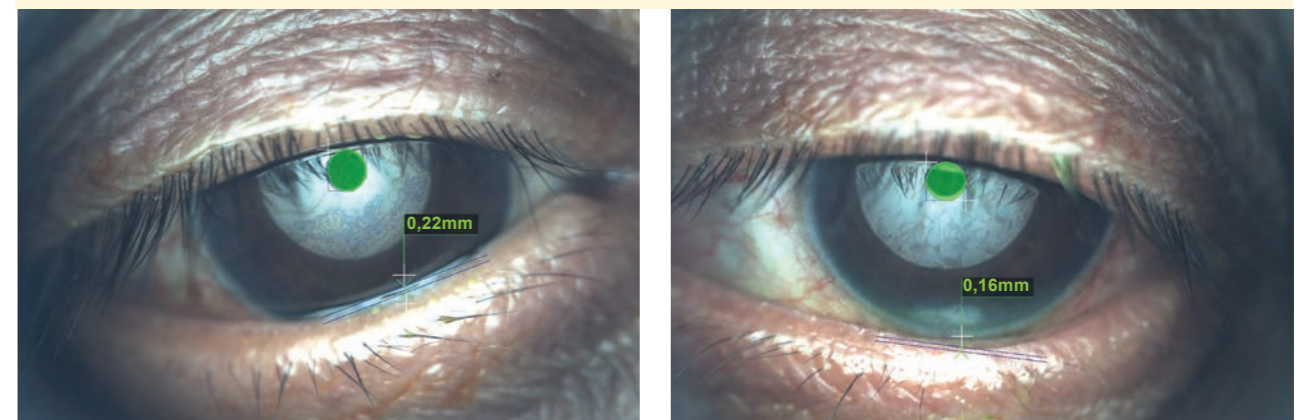
Lipid Layer Analysis

The Lipid analysis was good for OD eye with values greater than >80nm
The Lipid analysis for OS was <30nm



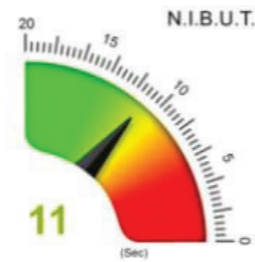
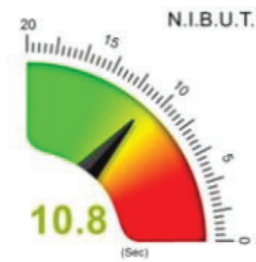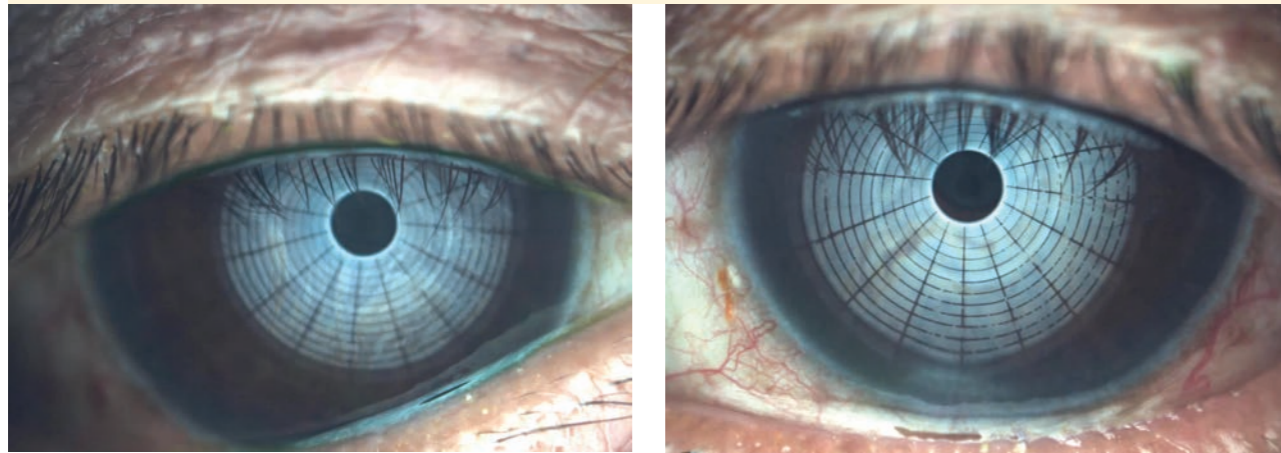
Tear Meniscus

The Ocular surface analyser showed normal tear meniscus height for OD as 0.22 mm and with less height for the OS eye at 0.16 mm



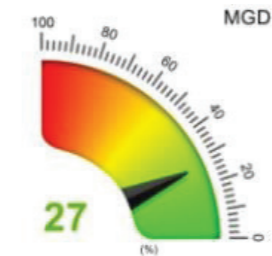
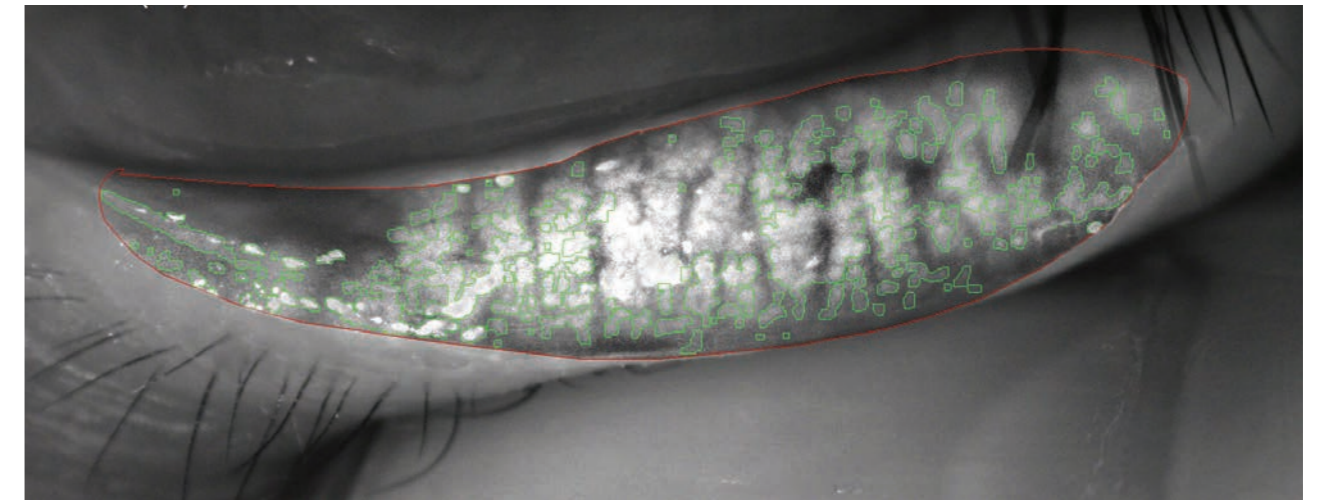
NIBUT Graph

The average NIBUT value reported for OD eye was 10.8 sec and for OS eye was 11.0 sec



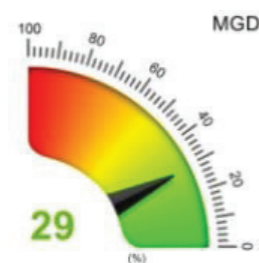
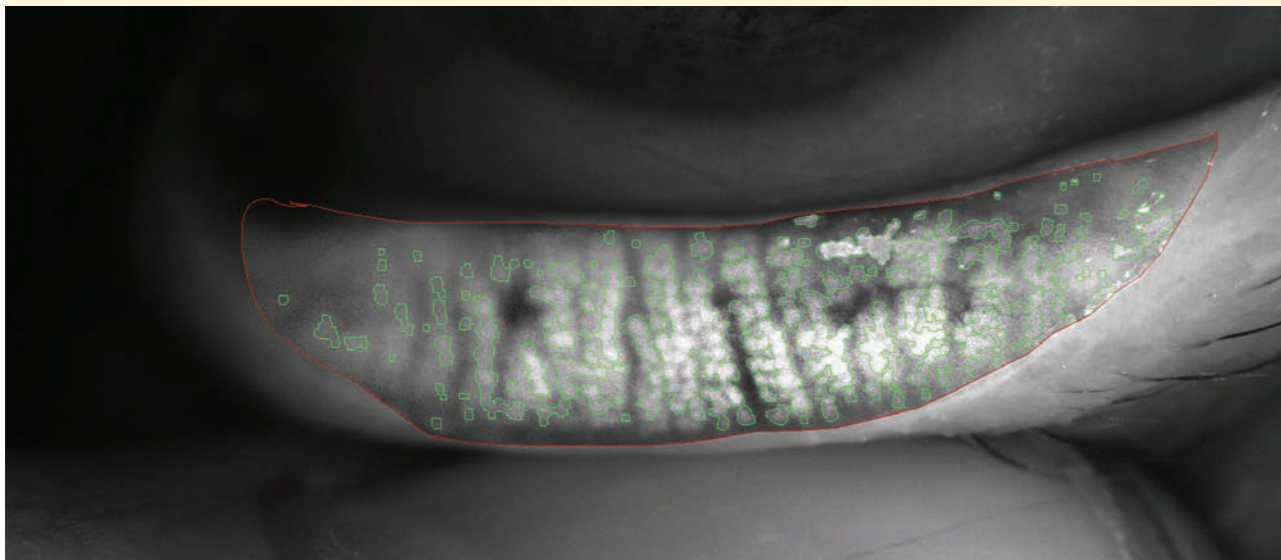
Conclusion

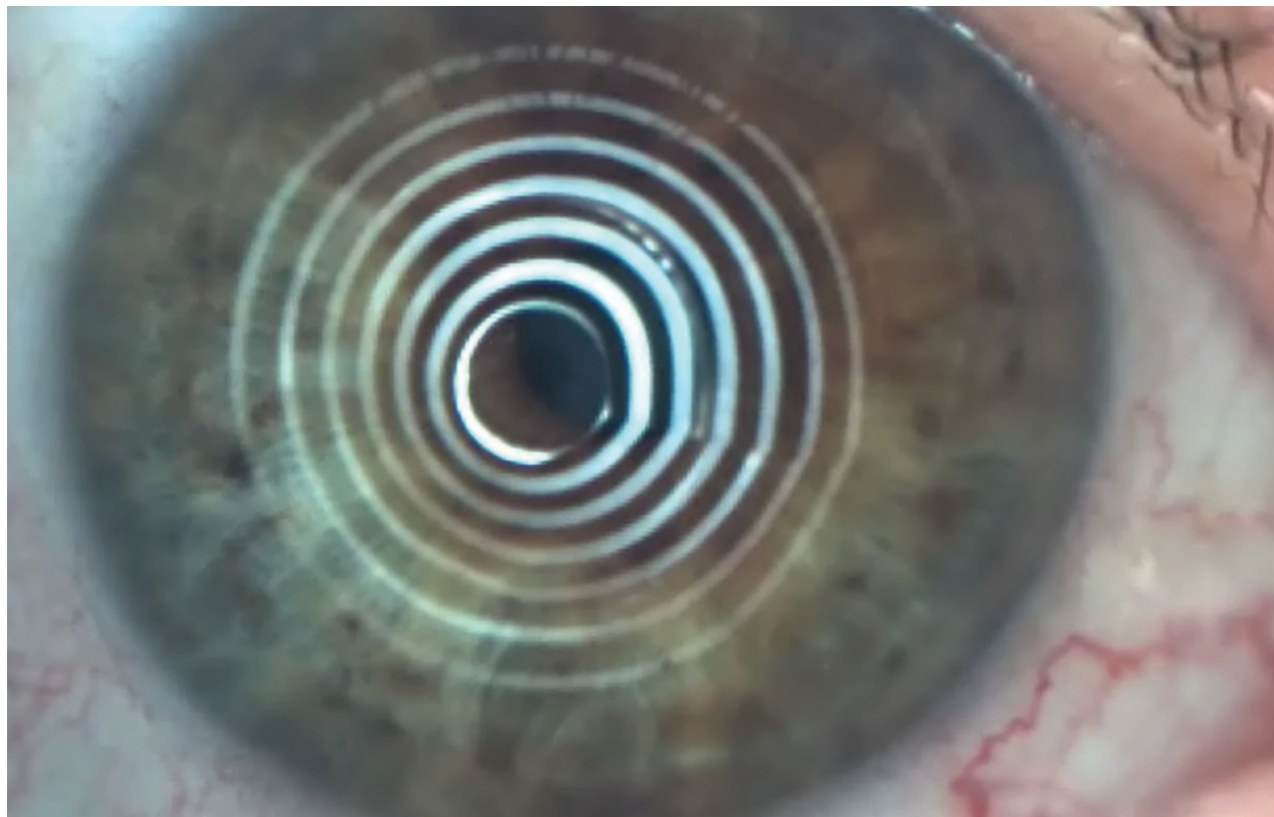
- After 2 IPL sittings The NIBUT values improved from earlier reported as 3sec for OD eye and 6 sec for OS Eye.
- Tearscope results correlate well in clinical findings.



MGD

The mgd analysis showed loss of % for OD eye and 20% for OS eye





Case 16 – Phacoemulsification follow-up

Dr. Franco Spedale
Dr. Francesco Blasetti

Head of the U.O. Ophthalmology
ASST-Franciacorta Hospital in Chiari (BS)
Italy

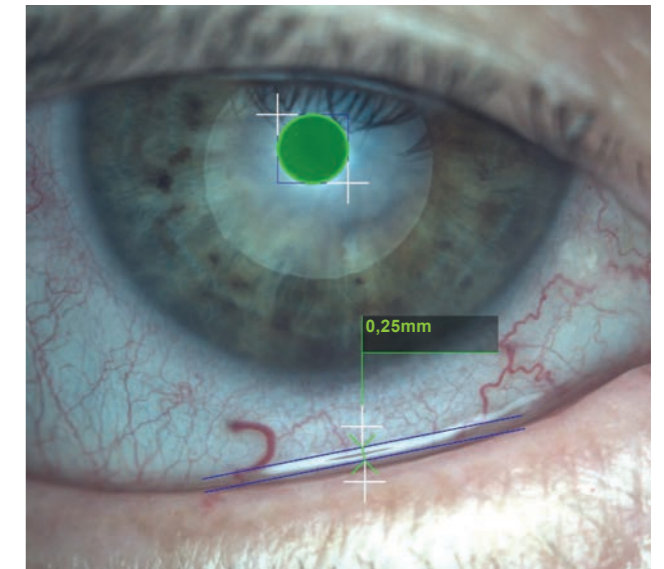
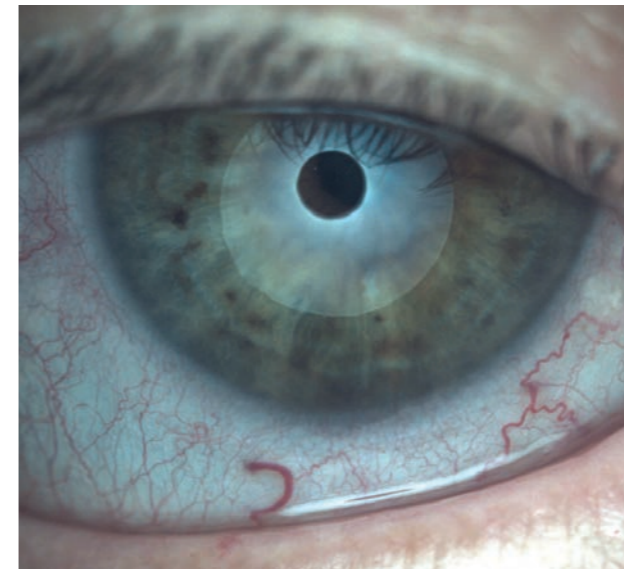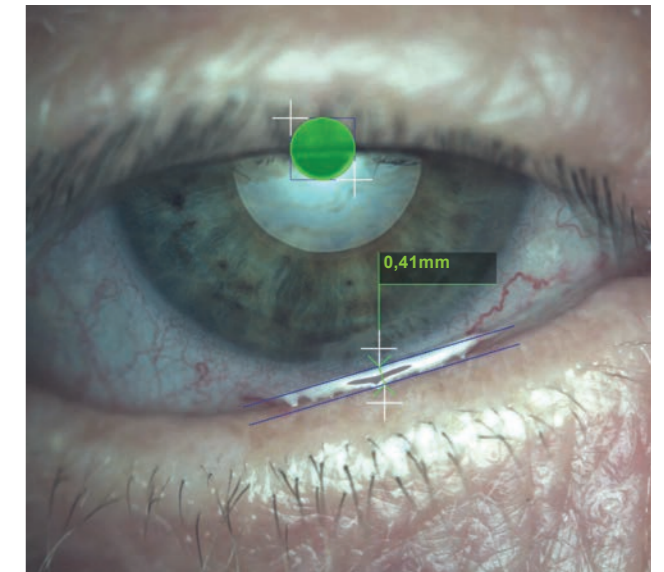
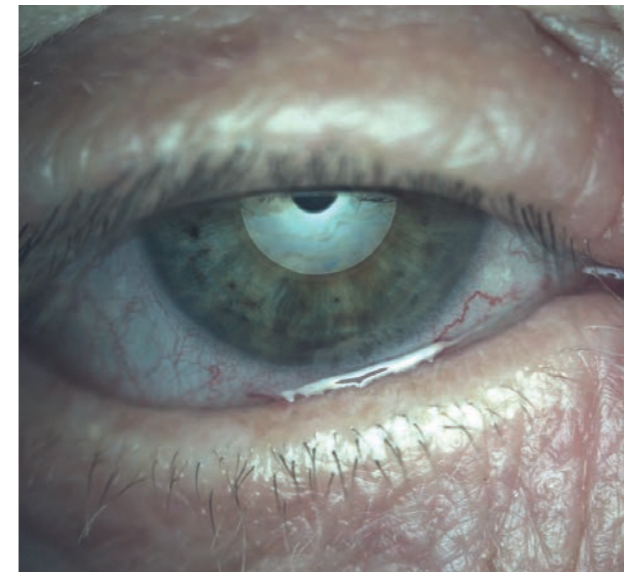
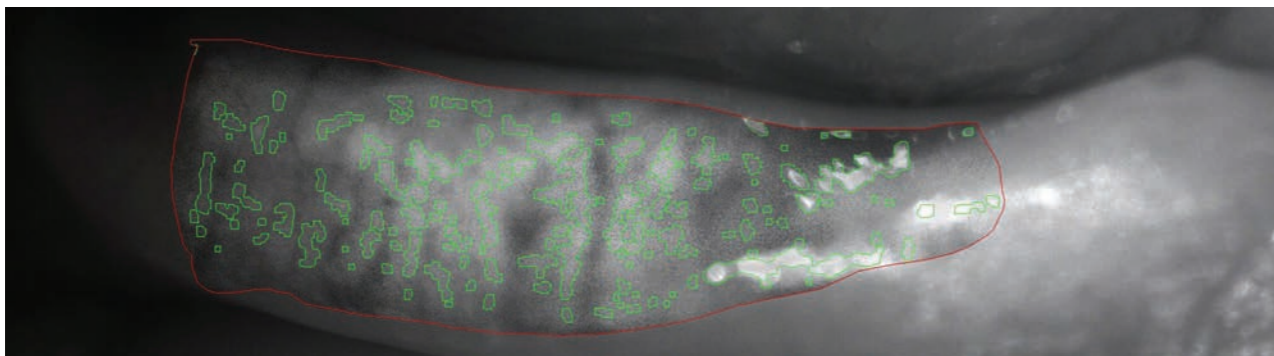
Patient's description

74-year-old woman with presence of cataract in the right eye.
She must deal with phacoemulsification and IOL implantation.
She does not report symptoms referable to dry eye, nor does she instill lacrimal substitutes.

Dysfunction description

The patient occasionally reports a foreign body sensation.
Her values 5 days before cataract surgery are as follows:

N.I.BUT: 12.5 sec
Tear meniscus: 0,41 mm
Interferometry: about 30 nm – closed reticulum
MGD evaluated on the lower eyelid shows loss area of about 37%.



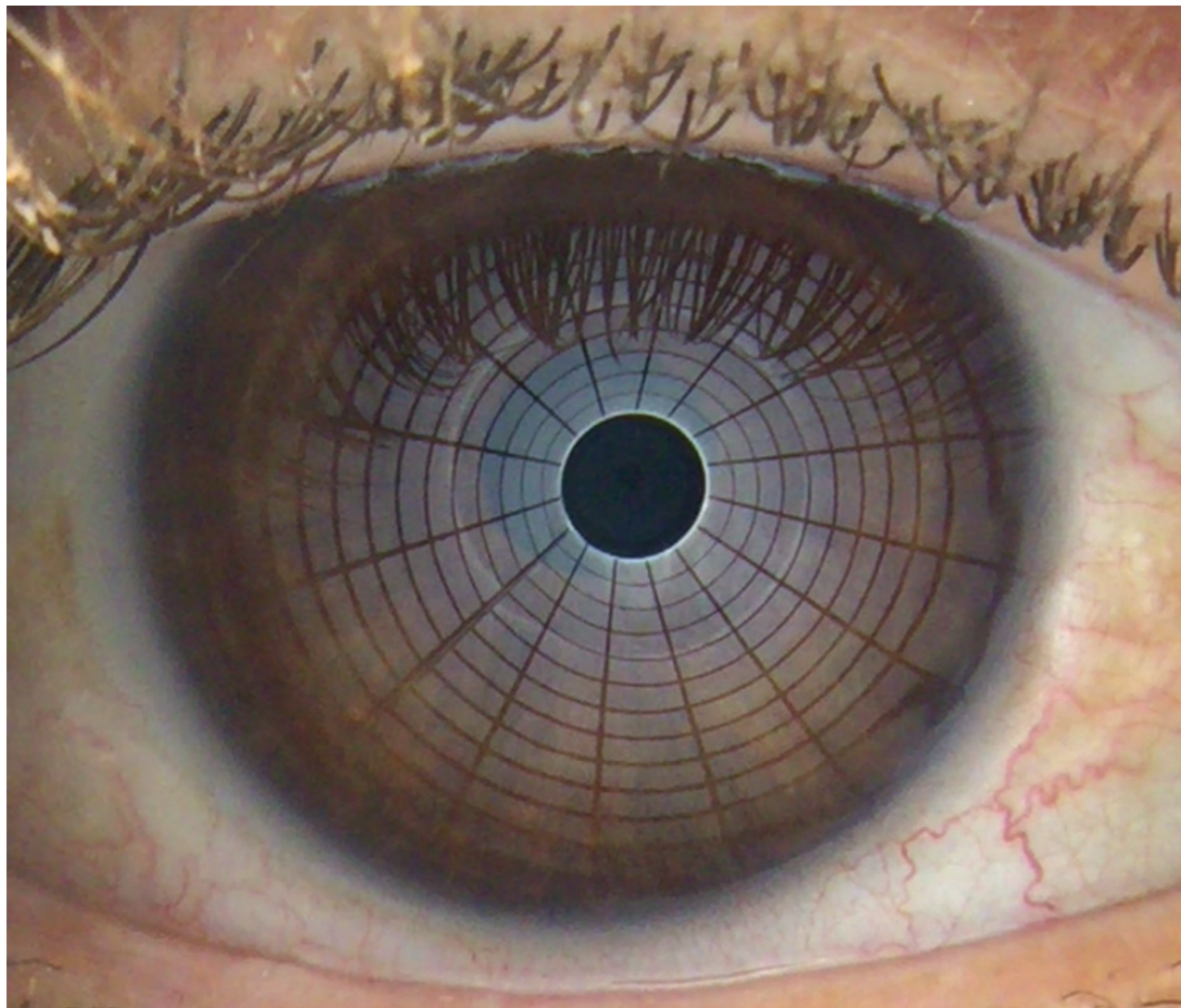
Exams comments

Prior to surgery, local anaesthesia was performed with lidocaine eye drops in the conjunctival fornix, disinfection of the periocular skin with 10% povidone iodate and of the bulbar conjunctiva with 5% povidone iodine. From this analysis it is clear that there has been a drastic reduction in the tear film breakage time, and a modest reduction of the lacrimal meniscus, a sign of a dry evaporative eye. The topical anaesthetic, the use of povidone iodate, the corneal cut, the affixing of the blepharostat induce important changes of the ocular surface that can lead to dry eye. This can have a negative impact on the patient operated and go to partly undermine the result of the operation. Therefore, the use of a tear substitute after cataract surgery is essential for the postoperative course and for the restoration of a correct ocular surface balance. The evaluation of the ocular surface before surgery allows to identify pre-existing dry eye problems and to better prepare the ocular surface for surgery with the most targeted therapeutic choice for each patient.

Values

(After 5 days from the cataract surgery)
Interferometry: 30 nm – closed reticulum
Tear Meniscus: 0,25 mm

NIBUT: 2.8 sec
Meibography: 51% loss evaluated on the lower eyelid



Case 17 – Evaporative Dry Eye

Dr. Sergio M. Solarino

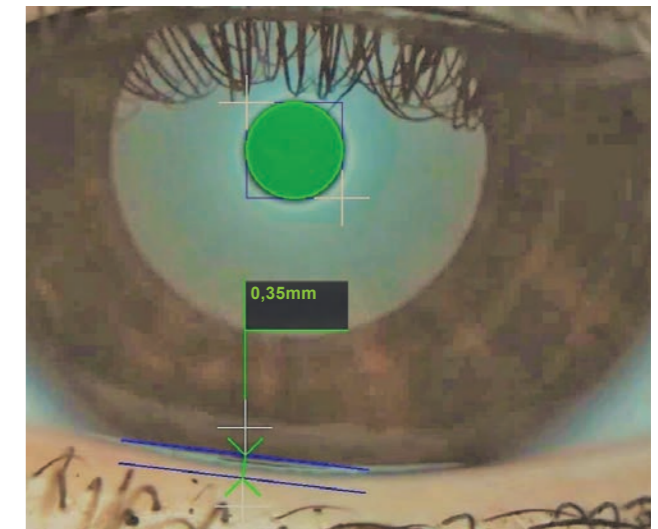
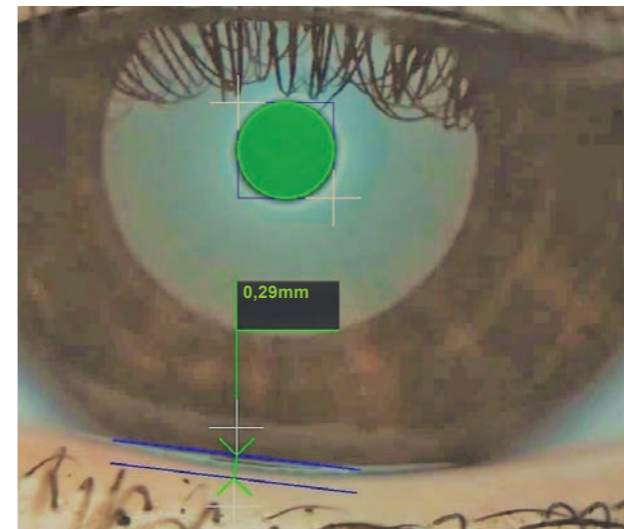
CentroVista, Sardinian Dry Eye Center
Cagliari-Selargius
Italy

Patient's description

45 years old female,
short sighted with heavy use of daily
disposable contact lenses
on chronic estrogen-progestin therapy.

Dysfunction description

The patient has complained for over a year of not being able to tolerate any more the daily disposable contact lenses for the same number of hours that she was used to. On awakening she complain of ocular burning with redness of the bulbar conjunctiva. sensation of foreign body present all day long and worsening in air-conditioned rooms. Transient and frequent blurring of the vision, especially when busy reading or at the computer. On the objective examination, she shows a normal cornea, no neovascularization at limbus but a diffuse conjunctival hyperaemia with important staining values.



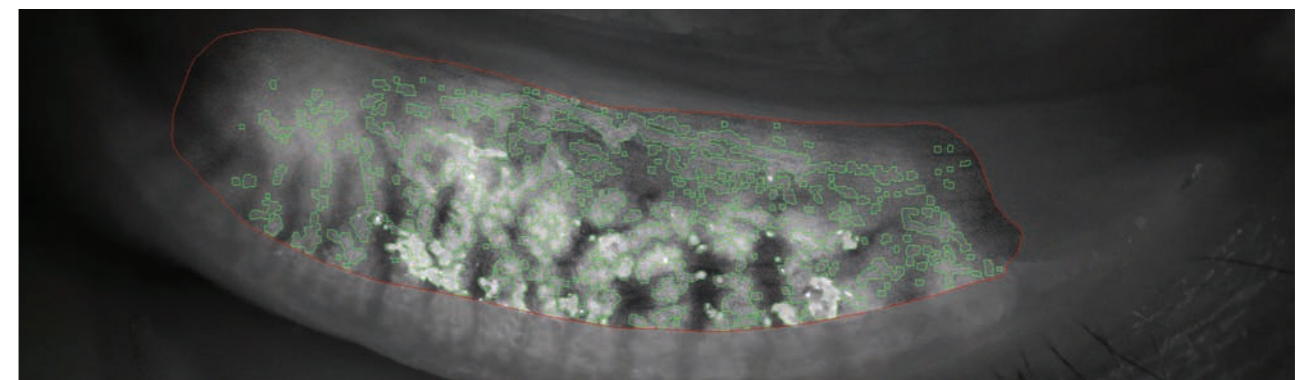
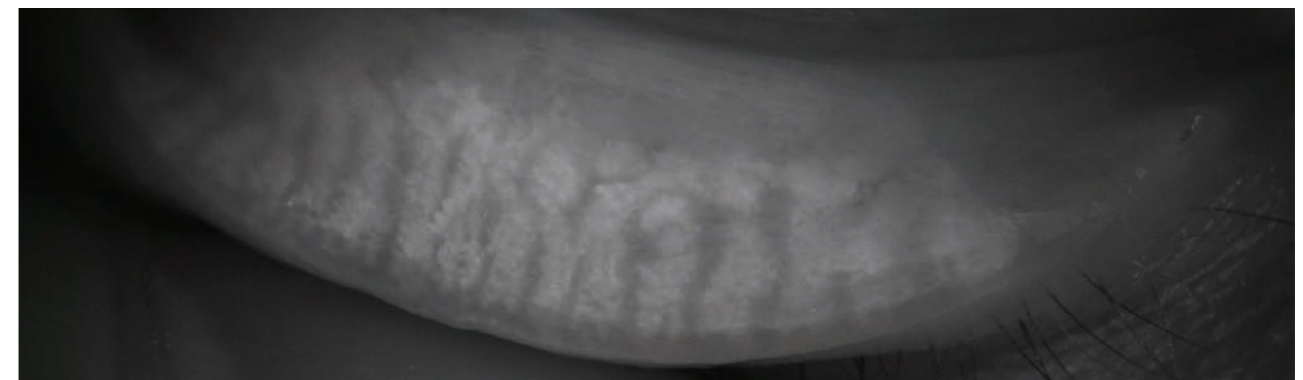Exams comments

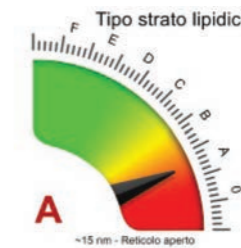
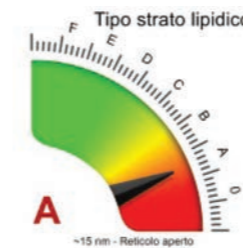
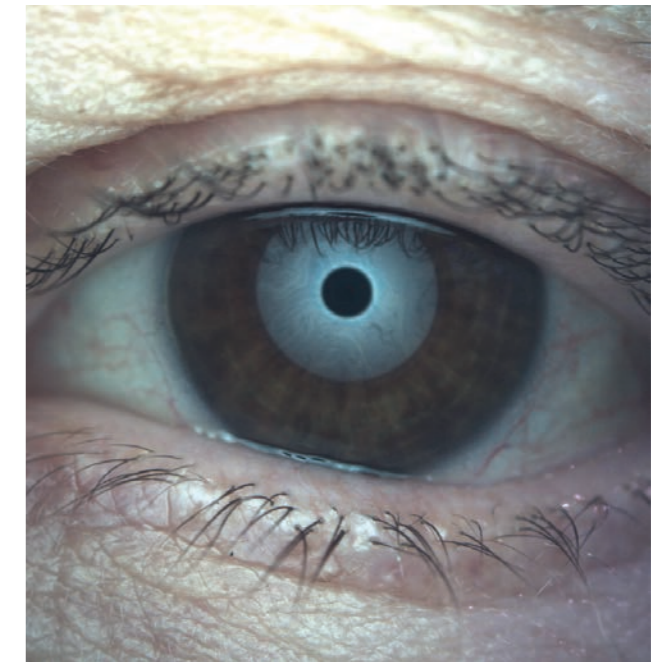
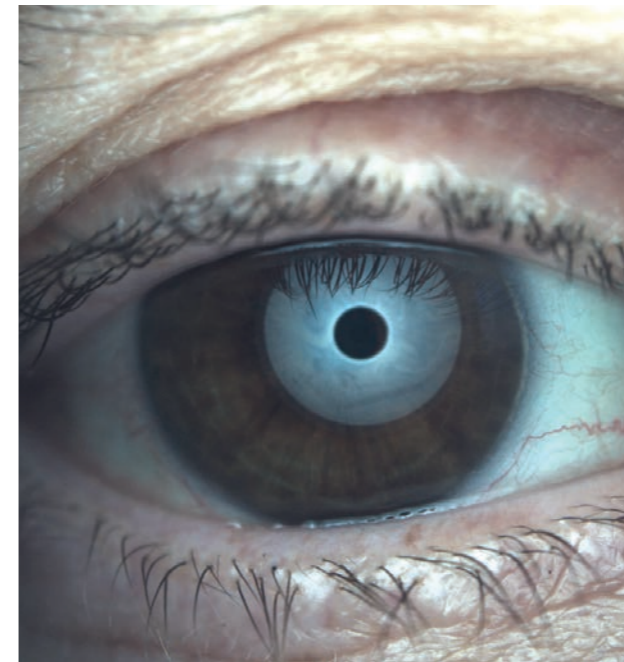
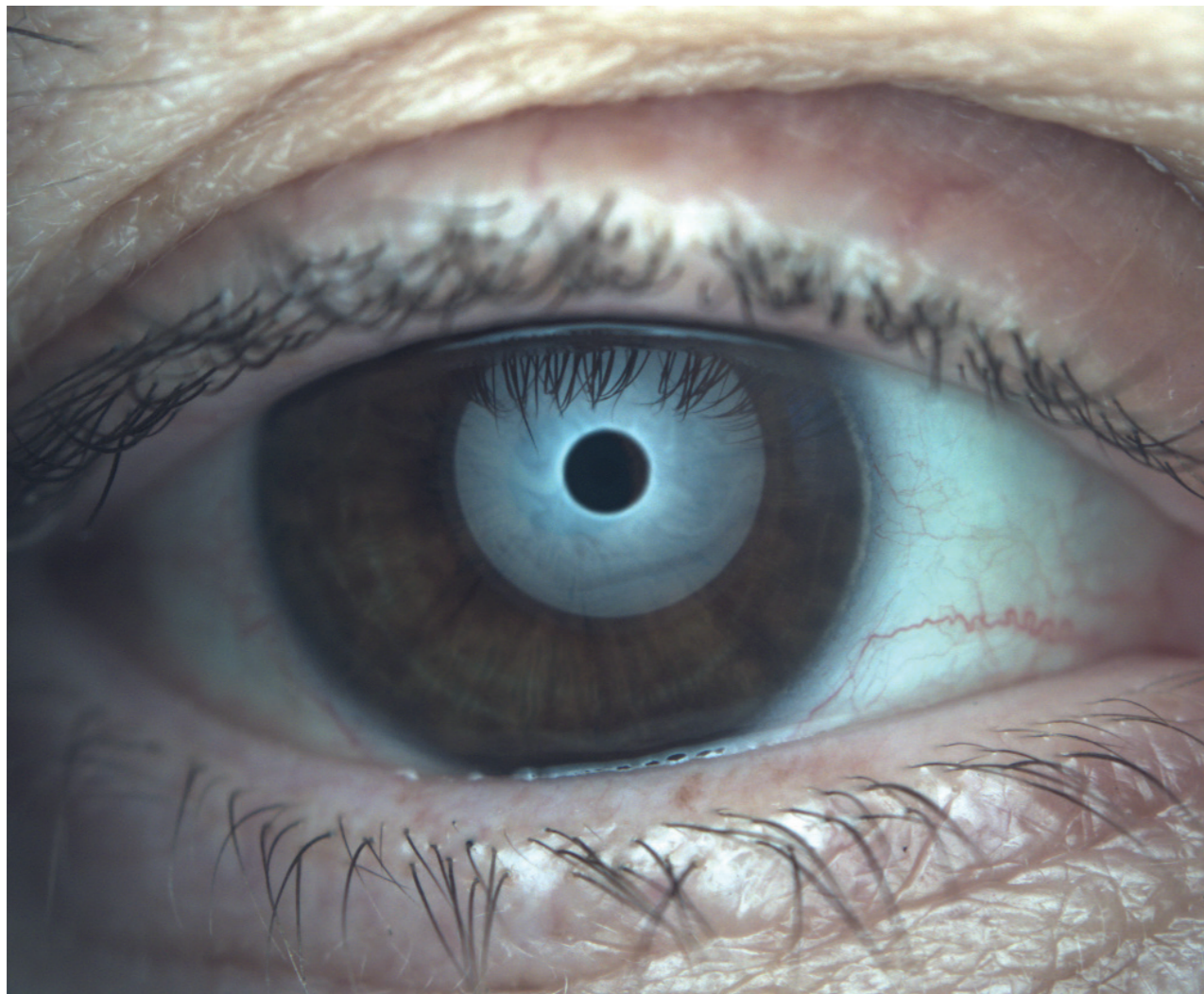
This patient is affected by an evaporative dry eye with involvement of meibomian glands of medium level. Her lipid component is poor and dysfunction of the Meibomian glands is about 30%. The estrogen-progestin chronic therapy and many years of contact lenses use are both important factors. She is on local therapy with tear substitutes with fatty acids for stabilizing the tear film and underwent IPL therapy and heating of the Meibomian glands, this together with massage and expression of meibomian glands for restarting proper secretion. We added also Ciclosporine 0,1% local drops BID and local desametasone drops preservative free BID.

Values

Interferometry: OD 30 nm OS: 30 nm
Tear Meniscus: OD: 0,35 mm, OS: 0,29 mm

NIBUT: OD 6,3 sec, OS: 4,3 sec
Meibography: OD 31% loss, OS: 22% loss





Case 18 – Meibomian gland dysfunction (MGD)

Dr. Sergio M. Solarino

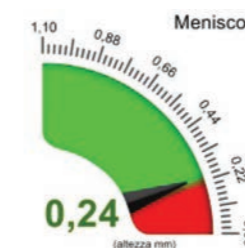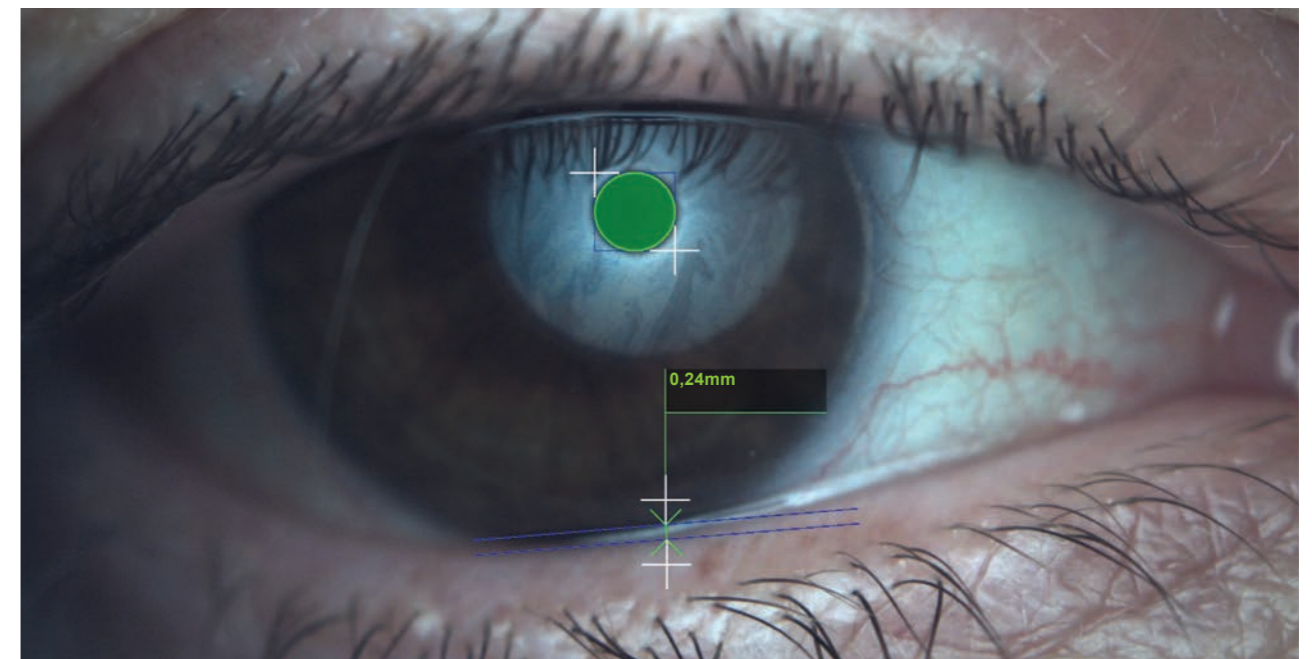
CentroVista, Sardinian Dry Eye Center
Cagliari-Selargius
Italy

Patient's description

62 years old, female,
medium short sighted (-5 sf)
BPCO in chronic therapy with Salbutamol
Sulphate BID
No previous ocular operation
Local therapy with Hyaluronic acid artificial tears

Dysfunction description

The patient presented to our clinic complaining about ocular symptoms lasting since about two years, like significant dryness during the night associated to bulbar conjunctival redness at awakening.
She also has been complaining about not being able anymore to tolerate the direct sunlight, especially during windy days.
Sometimes the symptoms are worsening with pain and foreign body sensation in both eyes.
On the objective examination, she shows a normal cornea, a diffuse conjunctival hyperemia with important staining values and mild vascular congestion on the lid margin of both upper and lower lids.



Exams comments

This patient is mainly affected by a meibomian gland disease and a mild evaporative dry eye. The involvement of meibomian glands is mild but prevalent. Her lipid component is poor and dysfunction of the Meibomian glands is about 20% and recovered rapidly with IPL treatment. Local therapy with tear substitutes with fatty acids for stabilizing the tear film was provided. She also underwent 3 IPL therapy cycle along with the heating of the Meibomian glands, performed with massage and expression of meibomian glands. Thus restarting a better secretion. We added local desametasone drops preservative free BID for two months.

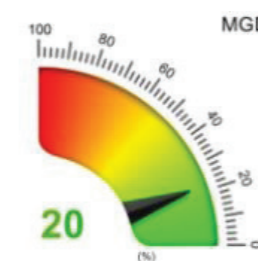
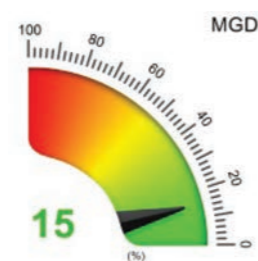
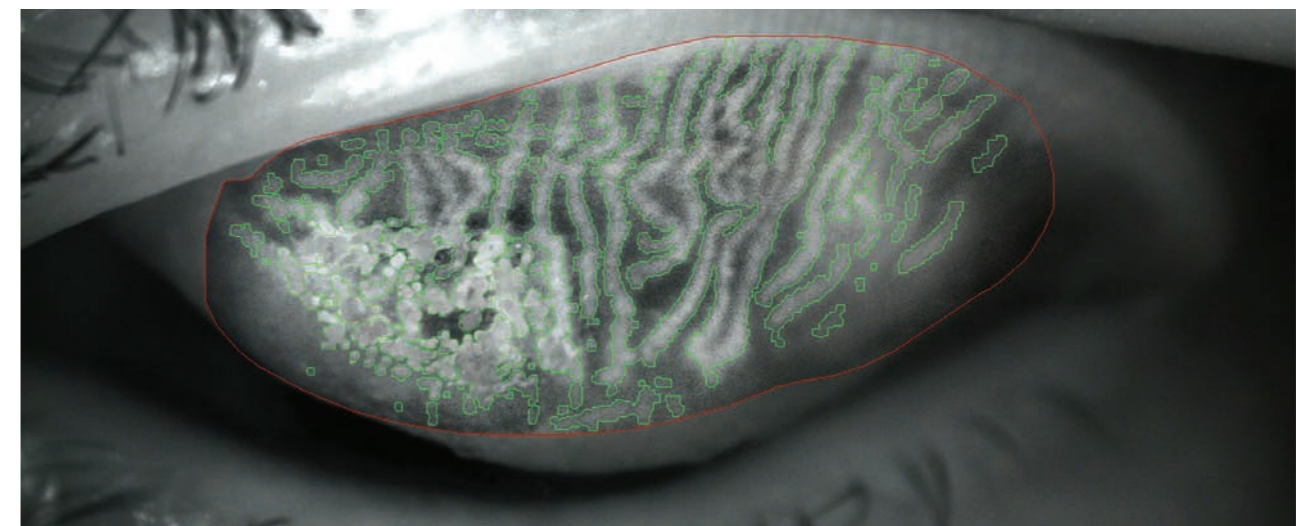
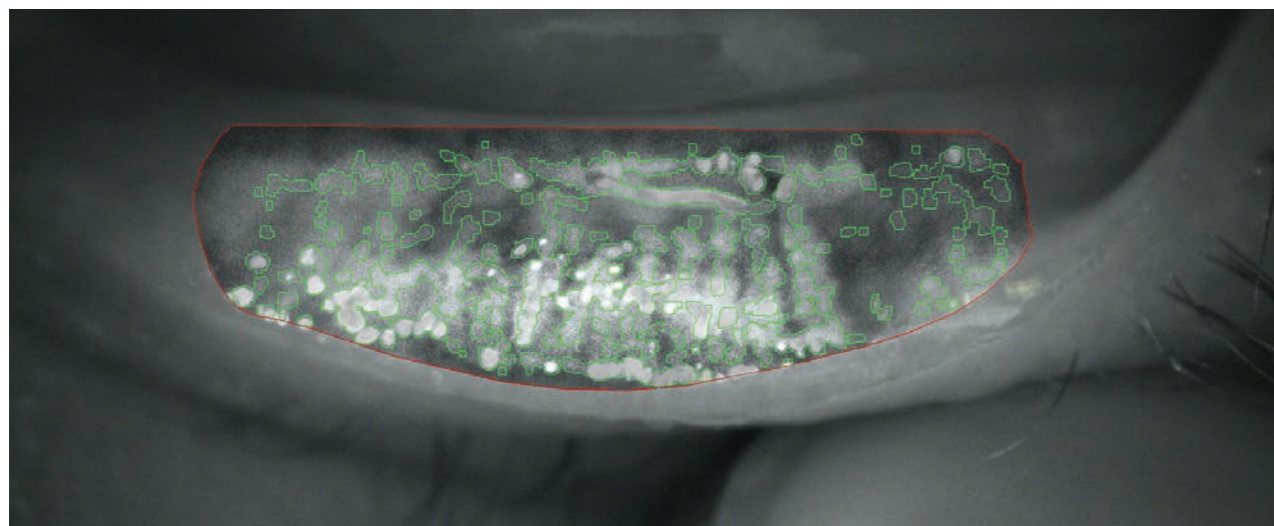
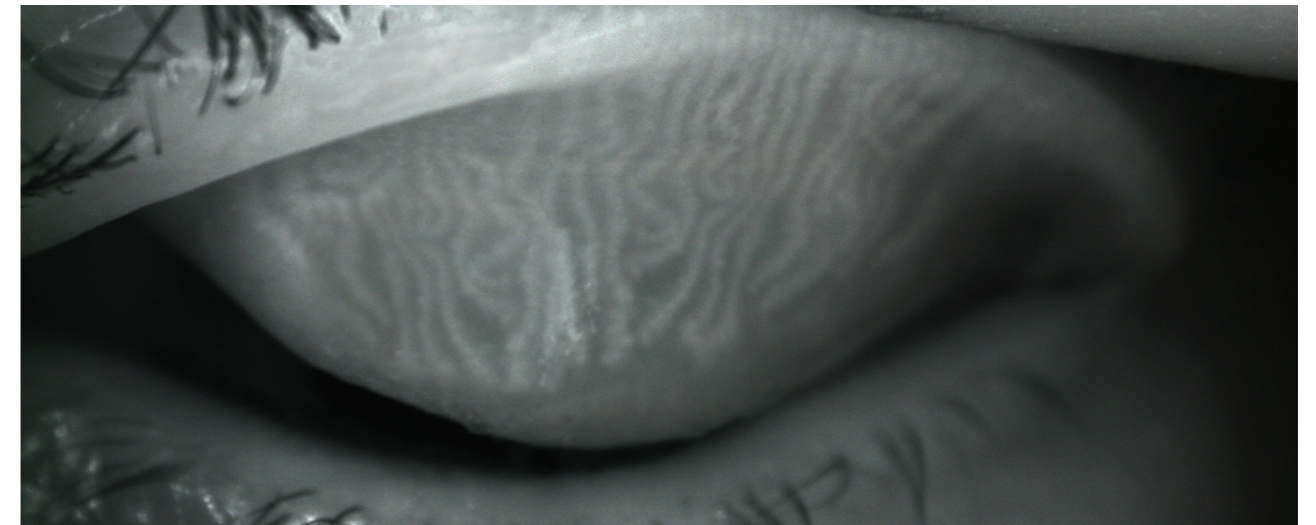
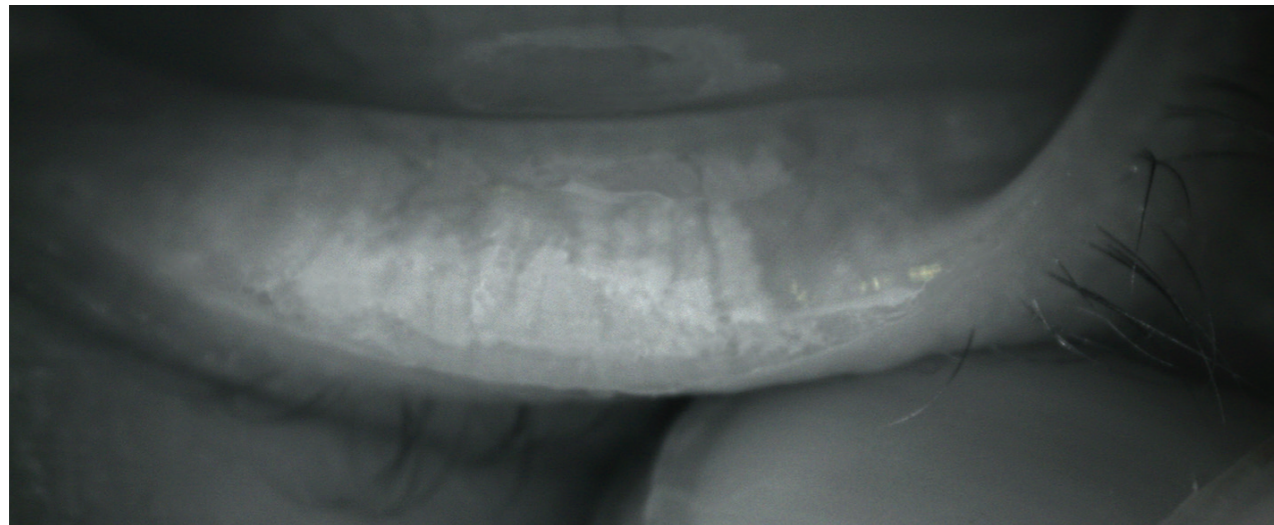
Values

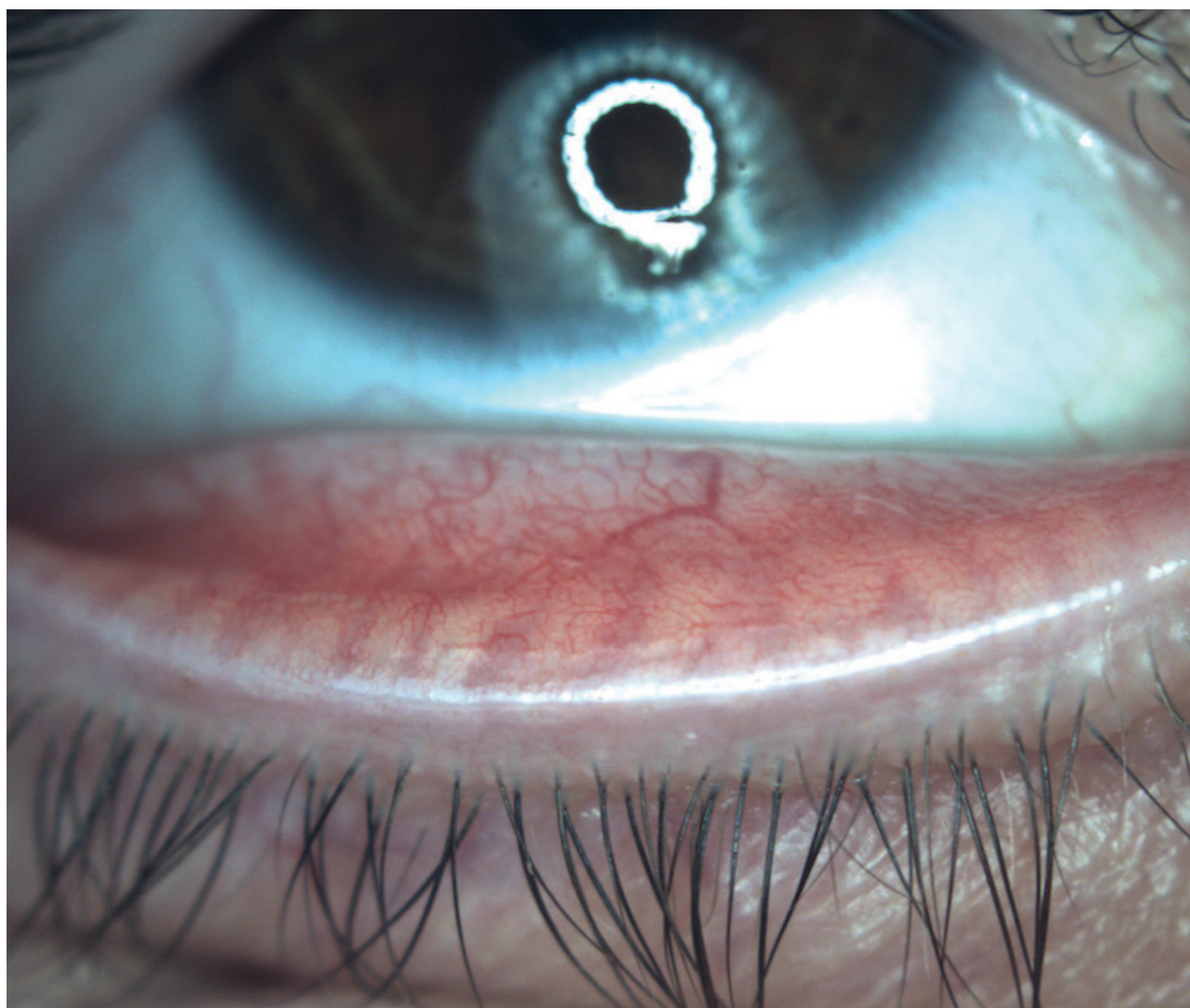
Interferometry: OD 30nm OS: 30 nm

NIBUT: OD 1,4 sec, OS: 2,3 sec

Tear Meniscus: OD: 0,24mm, OS: 0,26 mm

Meibography: OD 20% loss, OS:15% loss





Case 19 – Post Lasik Dry Eye

Dr. Sergio M. Solarino

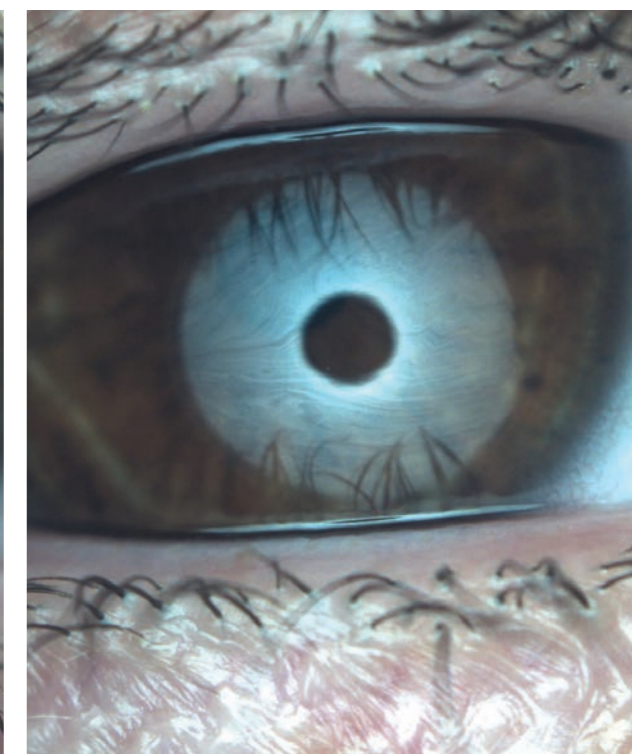
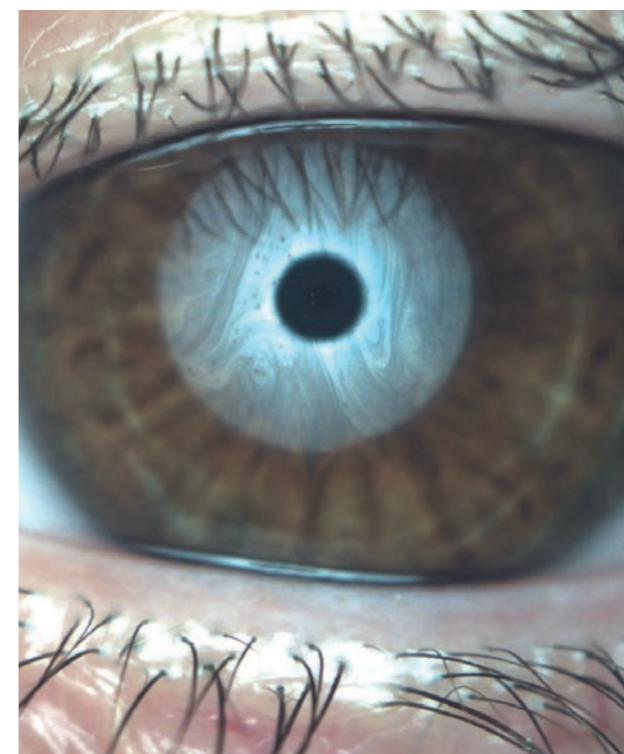CentroVista, Sardinian Dry Eye Center
Cagliari-Selargius
Italy

Patient's description

335 years old, male,
Medium short sighted (-4.5 sf) Underwent
LASIK in both eyes in 2014 Local therapy with
Hyaluronic acid artificial tears and occasionally
spontaneous use of tetryzoline eye drops.

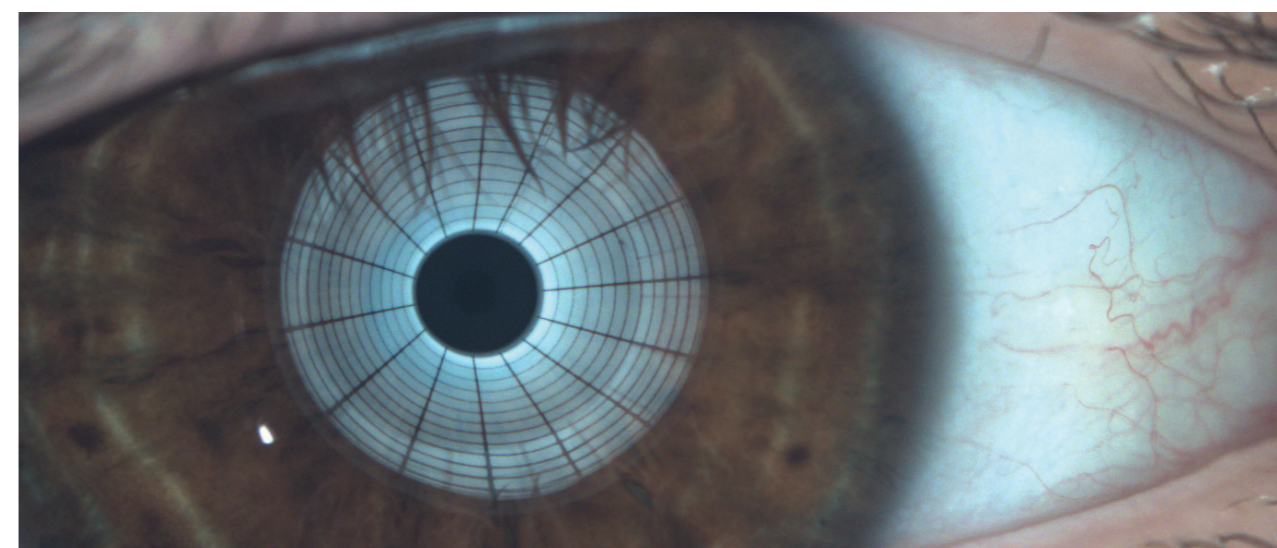
Dysfunction description

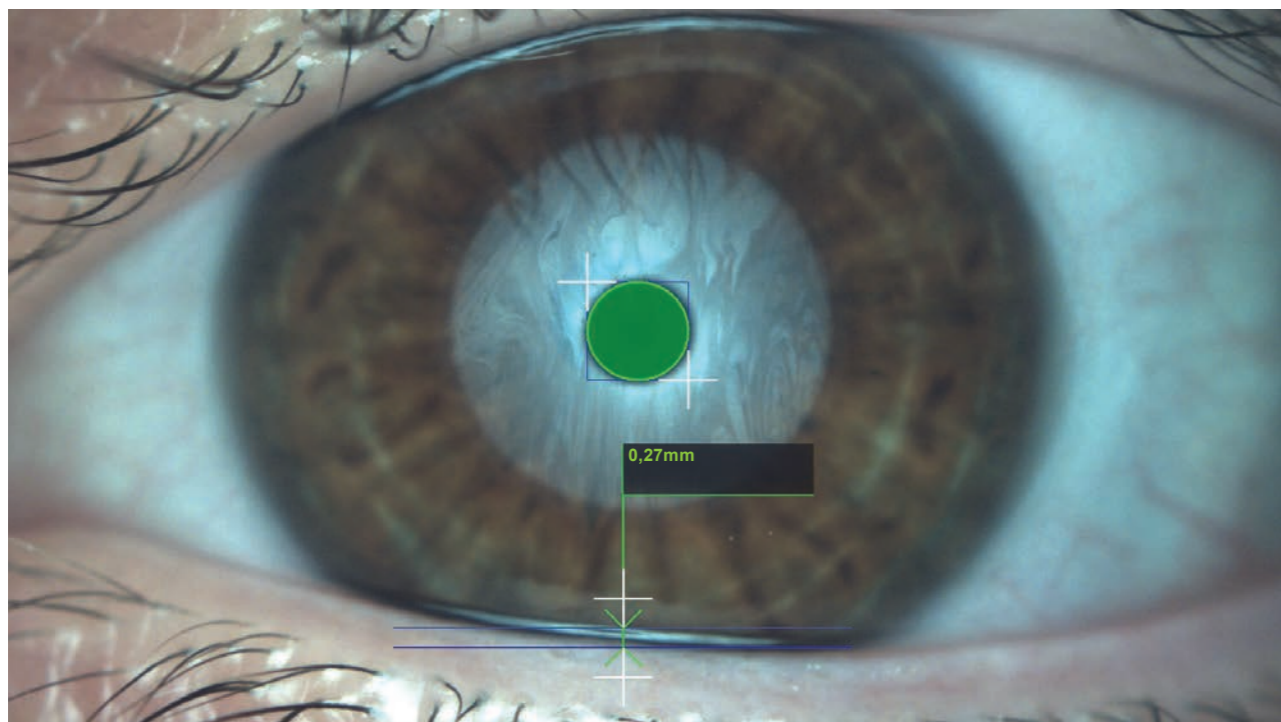
The patients complaints about low light glare,
dry eyes, night vision disturbance, associated to
bulbar conjunctival redness.
His Dry eye symptoms ranged from mild ocular
irritation to severe discomfort, occasionally,
mainly when applying to computer work for
many hours. Sometimes leading to photophobia
and blurred vision.
On the objective examination, he shows a
normal and transaperent cornea, a diffuse
conjunctival hyperemia with moderate staining
values and mild vascular congestion on the lid
margin of both upper and lower lids along with
some localized teleangiectasia.



Exams comments

This patient is mainly affected by a meibomian gland disease and a high evaporative dry eye.
He presented at first a very short time of NIBUT (1.2 s in OD and 1,7 in OS)
Interferometry is 30 nm in OD and 15 nm in OS
Tear meniscus is 26 mm in bothe eyes
Meibography shows 33 % loss in OD and 38% in OS
The involvement of meibomian glands is mild. His lipid component is poor and dysfunction of the
Meibomian glands decreased rapidly with IPL treatment.
Local therapy with tear substitutes with fatty acids for stabilizing the tear film was provided.
He also underwent 3 IPL therapy cicle along with the heating of the Meibomian glands, performed with
massage and expression of meibomian glands. Thus restarting a better secretion.
We added and local desametasone drops preservative free BID for two months.
Local use of Tetryzoline was interrupted.



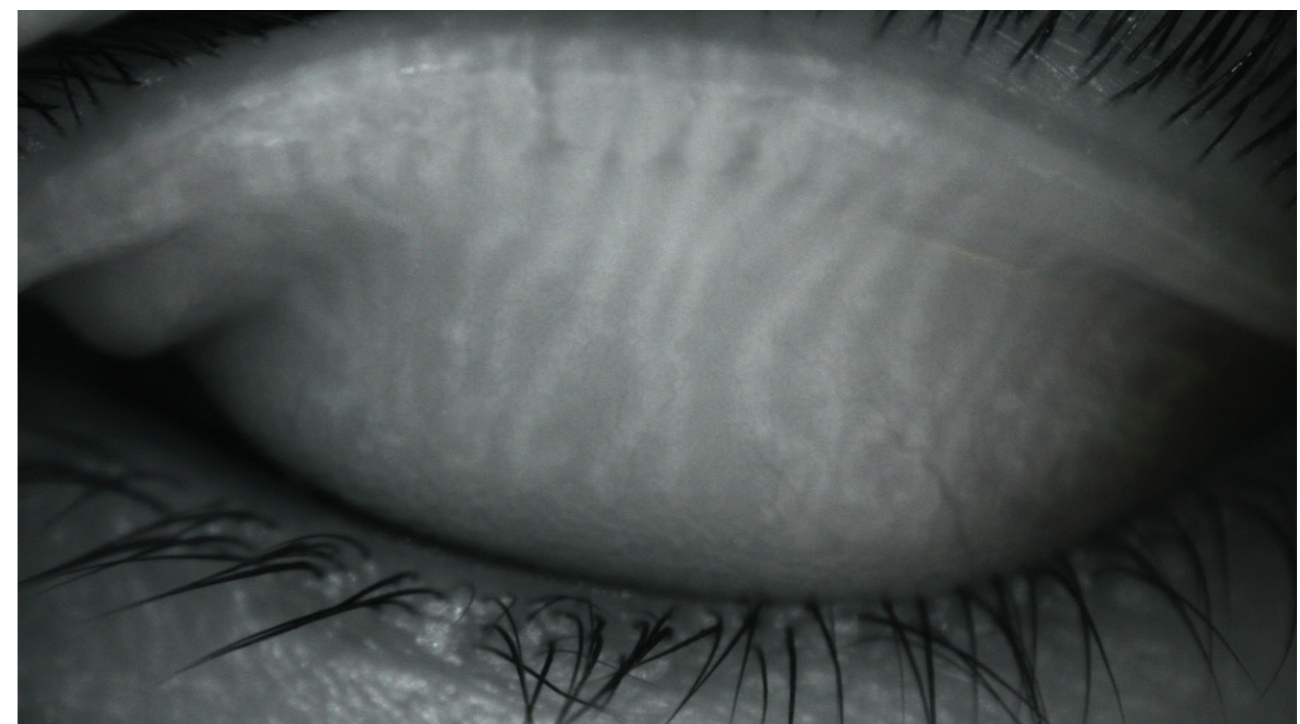
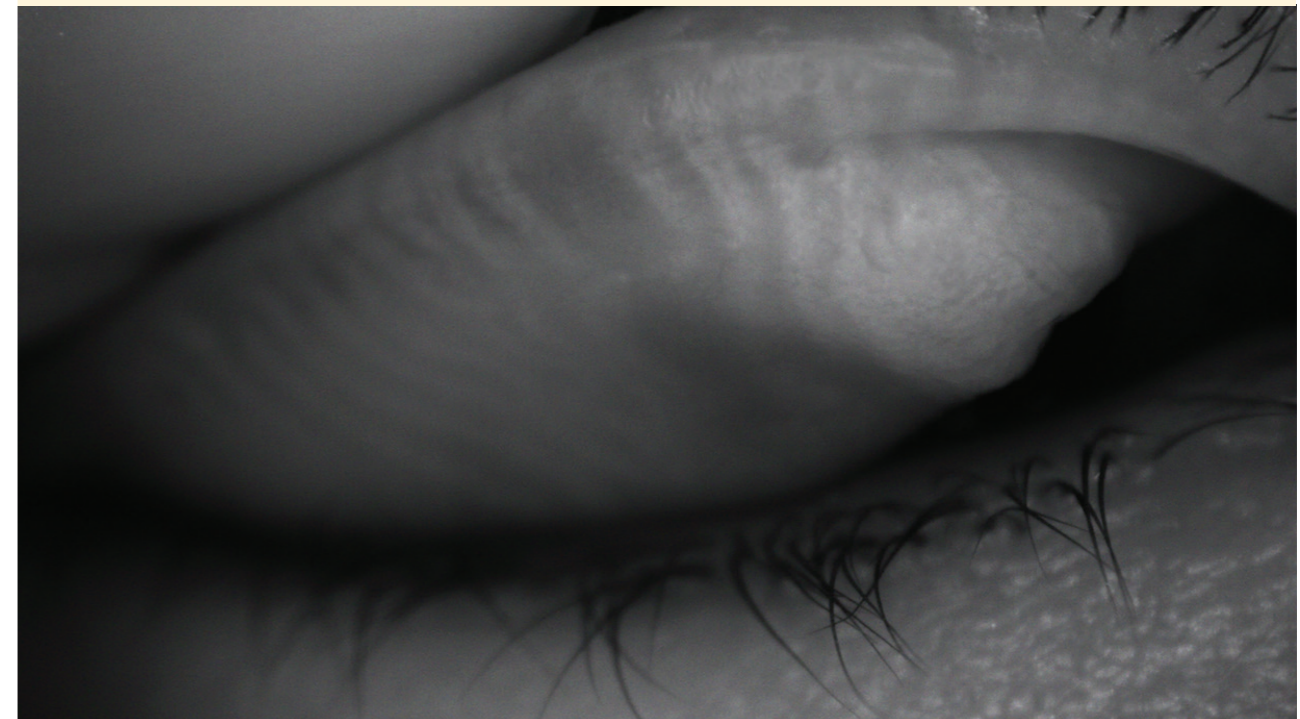


Values

Interferometry is 30 nm in OD and 15 nm in OS
 Tear Meniscus is 27 mm in bothe eyes

NIBUT (1.2 s in OD and 1,7 in OS)
 Meibography shows 33 % loss in OD and 38% in OS

Upper eyelids examination





Case 20 – Evaporative Dry Eye with conjunctival chalasis

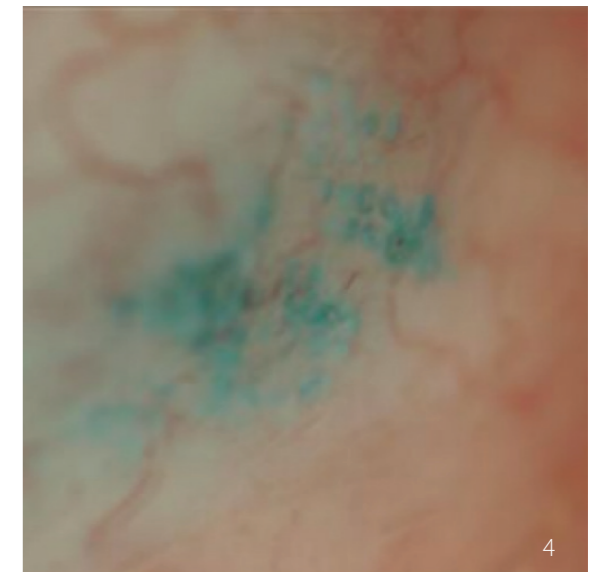
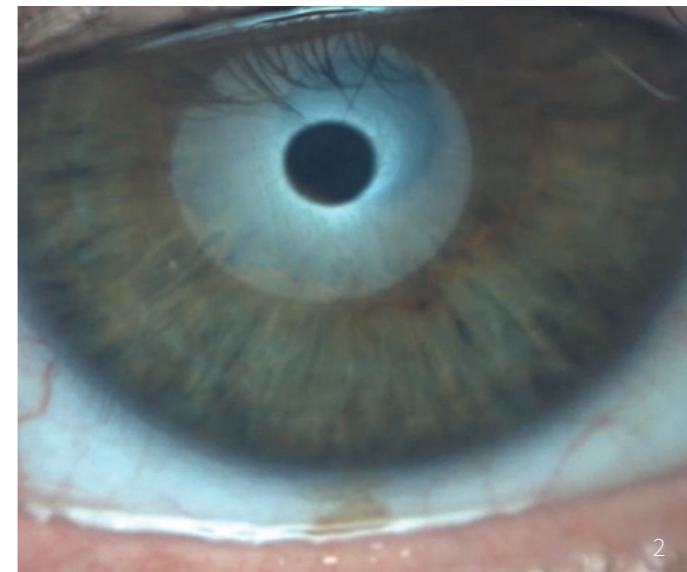
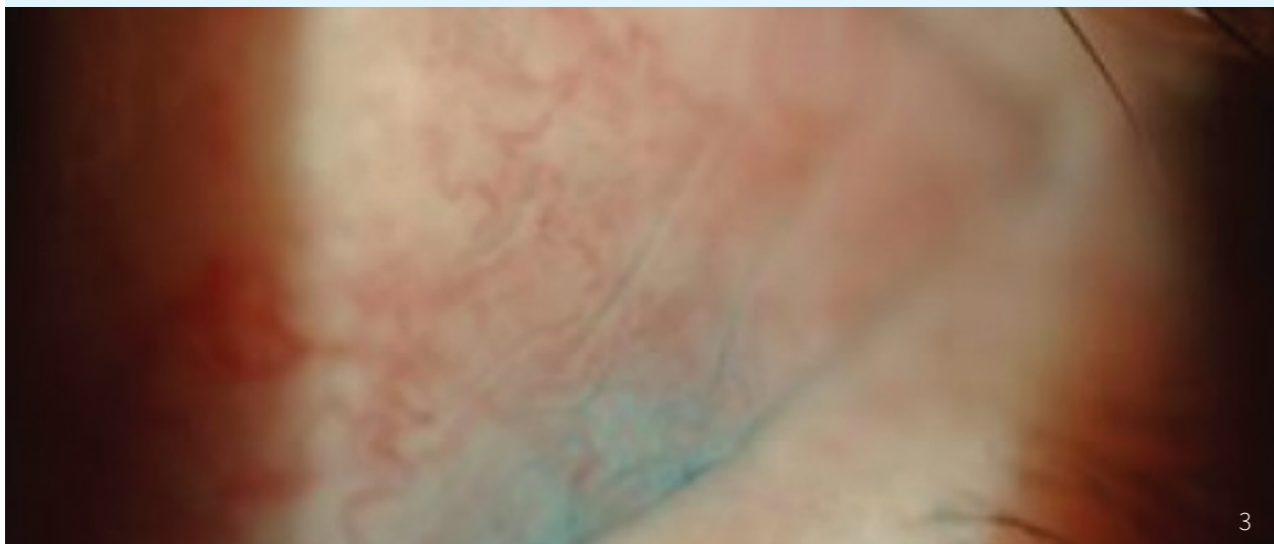Dr. Eros Radrizzani
Ambulatorio Superficie Oculare
Italy

Patient's description

72-year-old patient with SDL symptomatology. Treated for years with various formulations of eye drops (antibiotic Steroids without benefits) Currently he reports disorders like sensation of foreign body, itching, epiphora, heaviness in the evening and modest secretions on waking.

Dysfunction description

Local objectivity highlights aspects such as rounding of the palpebral edge, telagectasias, retractions of the glandular ducts, and moderate hyperemia which configures a picture of MGD of 3rd degree of chronic obstructive type. Combined with the presence of conjunctival folds at the outer 1/3 eyelid (conjunctival chalasis of 3rd degree lincoff scale).



Exams comments

The data show an O.S.D.I. of moderate dry eye (24), Osmolarity of a slight degree (309 mOsm/l) and interferometry with a poor or absent lipid layer, reduced and interrupted meniscus due to the presence of conjunctival chalasis, rapid NIBUT.

The analysis of the data led to the highlighting of a picture of chronic evaporative dry eye due to obstructive glandular dysfunction complicated by the presence of abundant conjunctival chalasis.

In the treatment the main objectives were:

- To solve the presence of conjunctival chalasis,
- To make a good lipid layer in the tear film to limit the abundant evaporation,
- To reduce the inflammatory state.

In the first case, I used an Argon laser treatment on the third external of bulbar conjunctiva towards the lower fornix with 2-3 spots lines, after instilling lissamine (Fig. 3 and 4).

After the treatment, I combined external antibiotic and steroids three times a day, decreasing the dose in twenty days and exploiting the anti-inflammatory action on the clinical picture.

In addition, the patient used lipidic artificial tears 4-5 times a day for two months and Omega 3 and Omega 6 supplements for one month.

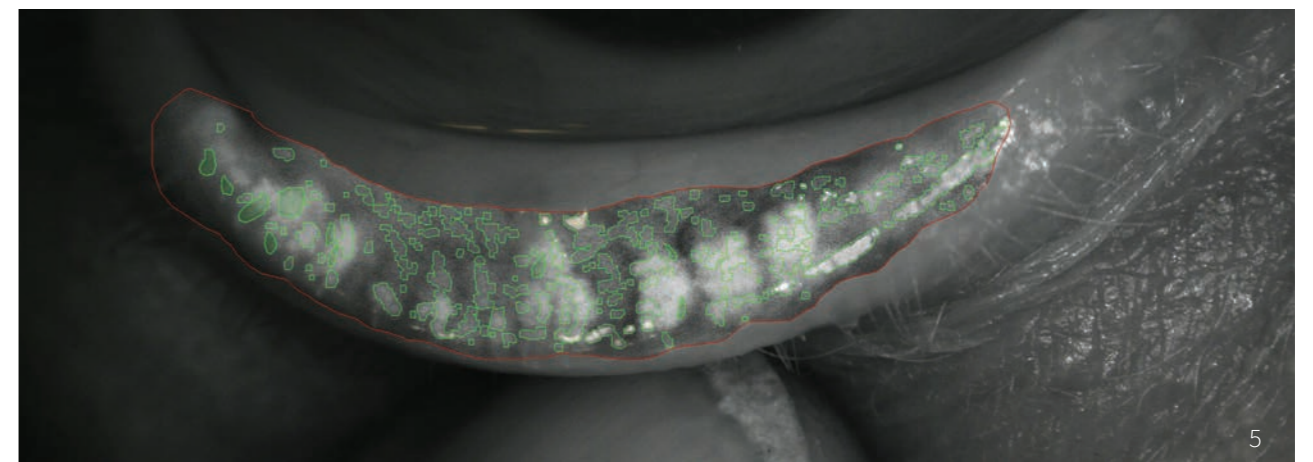
Values

Interferometry: 15nm

NIBUT: 4,4s

Tear Meniscus: 0,22 mm

Meibography: 39%



3) Conjunctival chalasis: coloration with Lissamina green

4) Reduced tear meniscus 0,22 mm

5) Meibography: Glandular loss of 39%; Obstruction of the ducts and lobular dilatation.

SCIENTIFIC ARTICLE BY CORNEA

CLINICAL SCIENCE

Ocular Surface Workup With Automated Non-invasive Measurements for the Diagnosis of Meibomian Gland Dysfunction

Giuseppe Giannaccare, MD, PhD,* Luca Vigo, MD,† Marco Pellegrini, MD,* Stefano Sebastiani, MD,* and Francesco Carones, MD†

Purpose: To analyze diagnostic performance of an ocular surface workup based on automated non-invasive measurements in the diagnosis of meibomian gland dysfunction (MGD).

Methods: Two hundred ninety-eight eyes of 149 patients with MGD and 54 eyes of 27 control patients were analyzed. Ocular Surface Disease Index (OSDI), non-invasive breakup time (BUT), lipid layer thickness, meibomian gland loss, and tear osmolarity were calculated. The correlations among variables in the MGD group were analyzed. The area under the curve (AUC) of receiver operating characteristic curves was calculated.

Results: OSDI, non-invasive BUT, and meibomian gland loss were significantly different between MGD and control groups (respectively, 37.9 vs 19.6 vs. 7.1 vs 2.8; 8.8 vs 3.6 vs. 11.0 vs 3.0; 28.0 vs

17.6 vs. 21.2 vs 13.0; always $P < 0.05$). Positive correlations were found between lipid layer thickness and non-invasive BUT and between meibomian gland loss and OSDI (respectively, $r = 0.169$, $P = 0.004$; $r = 0.187$, $P = 0.004$). Non-invasive BUT had the highest diagnostic power as a single parameter, followed by meibomian gland loss (respectively $AUC = 0.686$, $AUC = 0.598$). When the diagnosis of MGD was made based on either non-invasive BUT or meibomian gland loss being abnormal, sensitivity was 86.2% and specificity 38.5%. When the diagnosis was made on both non-invasive BUT and meibomian gland loss being abnormal, sensitivity was 39.3% and specificity 85.6%.

Conclusions: This automated non-invasive ocular surface workup may represent a useful screening tool for the diagnosis of MGD. In case of positivity of either non-invasive BUT or meibomian gland loss, subsequent qualitative clinical tests should be performed to achieve a reliable diagnosis and more precise characterization of MGD.

Received for publication October 11, 2017; revision received November 2, 2017; accepted November 8, 2017.

From the *Ophthalmology Unit, DIMES, S.Orsola-Malpighi University Hospital, University of Bologna, Bologna, Italy; and †Carones Ophthalmology Center, Milan, Italy.

The authors have no funding or conflicts of interest to disclose. G. Giannaccare and L. Vigo contributed equally and should be considered co-first authors.

Reprints: Giuseppe Giannaccare, MD, PhD, Ophthalmology Unit, S.Orsola-Malpighi Teaching Hospital, University of Bologna, Via Palagi

9, 40138 Bologna, Italy (e-mail: giuseppe.giannaccare@gmail.com). Copyright © 2018 Wolters Kluwer Health, Inc. All rights reserved.

Key Words: meibomian gland dysfunction, non-invasive breakup time, lipid layer thickness, meibography, tear osmolarity (Cornea 2018;0:1–6)

Dry eye disease was recently redefined as a "multifactorial disease of the ocular surface characterized by a loss of homeostasis of the tear film, and accompanied by ocular symptoms, in which tear film instability and hyperosmolarity, ocular surface inflammation and damage, and neurosensory abnormalities play etiological roles."¹ Meibomian gland dysfunction (MGD) represents the leading cause of evaporative dry eye, the most common subtype of dry eye.^{2,3} MGD is characterized by hyperkeratinization of the meibomian gland ductal epithelium, leading to obstruction and plugging of the gland orifice. Moreover, quantitative and qualitative changes in the meibum lipid composition lead to increased viscosity and reduced gland outflow onto the tear film. The stasis of meibum inside the gland promotes proliferation of bacteria, producing lipases and esterases that increase the viscosity and melting temperature of the meibum, thus setting up a vicious spiral. Hyposecretion of meibomian lipids causes thinning of the tear film lipid layer, with consequent tear film instability, increased evaporation rate, and dry eye onset.^{4–6}

There is currently no general consensus regarding the diagnostic workup for the diagnosis of MGD and monitoring of the treatment response. Routinely, the diagnosis is mainly based on slit-lamp examination of the lid margin and ocular surface epithelium, meibomian gland expressibility and secretion quality, and fluorescein tear breakup time (BUT).⁷ However, these tests are invasive, requiring direct contact with the ocular surface, and subjective, which leads to the possibility of significant observer bias because of a low degree of standardization.⁸ Recently, newer automated and non-invasive tests, including among others, non-invasive BUT, lipid layer thickness, tear osmolarity and noncontact meibography, have been developed to complement the diagnosis of MGD and dry eye disease. The purpose of this study was to analyze diagnostic performance of an ocular surface workup based on the above-mentioned automated non-invasive measurements in the diagnosis of MGD.

MATERIALS AND METHODS

Study Population

This cross-sectional study was conducted at Carones Ophthalmology Center (Milan, Italy) between September 2016 and July 2017. The study was performed in accordance with the principles of the Declaration of Helsinki and was approved by the local institutional review board. Written informed consent was obtained from all subjects before the examination. Patients with ocular discomfort symptoms (OSDI ≥ 13) and at least one clinical sign of MGD (namely terminal duct obstruction, plugging of the meibomian glands, turbid secretions, inflammation and swelling of the eyelid margin, or poor meibum expression) were enrolled in the MGD group. Healthy sex and age-matched patients acted as the control group. The exclusion criteria for both groups were age less than 18 years, concomitant presence of systemic uncontrolled disease, any active ocular surface disease other than MGD (including aqueous tear-deficient dry eye disease), and previous ocular trauma or surgery.

Ocular Surface Workup

Before any examination, all patients completed the Ocular Surface Disease Index (OSDI) questionnaire to assess the severity of ocular surface symptoms. After slit-lamp examination, the following tests were performed in the following chronological order: non-invasive BUT, lipid layer thickness, tear osmolarity, and noncontact meibography of the lower eyelid.

The OSDI questionnaire consists of 12 questions regarding the presence and frequency of symptoms related to the ocular surface. The final scale ranges from 0 to 12 (no disability), to 13 to 22 (mild symptoms), to 23 to 32 (moderate symptoms), and to 33 to 100 (severe symptoms). The non-invasive BUT and lipid layer thickness were assessed by interferometry using the I.C.P. Tearscope (SBM Sistemi, Turin, Italy). Three measurements of the non-invasive BUT were recorded, and the median value was used for statistical analysis. The lipid layer thickness was graded from 0 to 5 based on the observed lipid layer patterns: absence of lipids (grade 0); open meshwork (grade 1); tight meshwork (grade 2); waves (grade 3); amorphous (grade 4); and color mixing

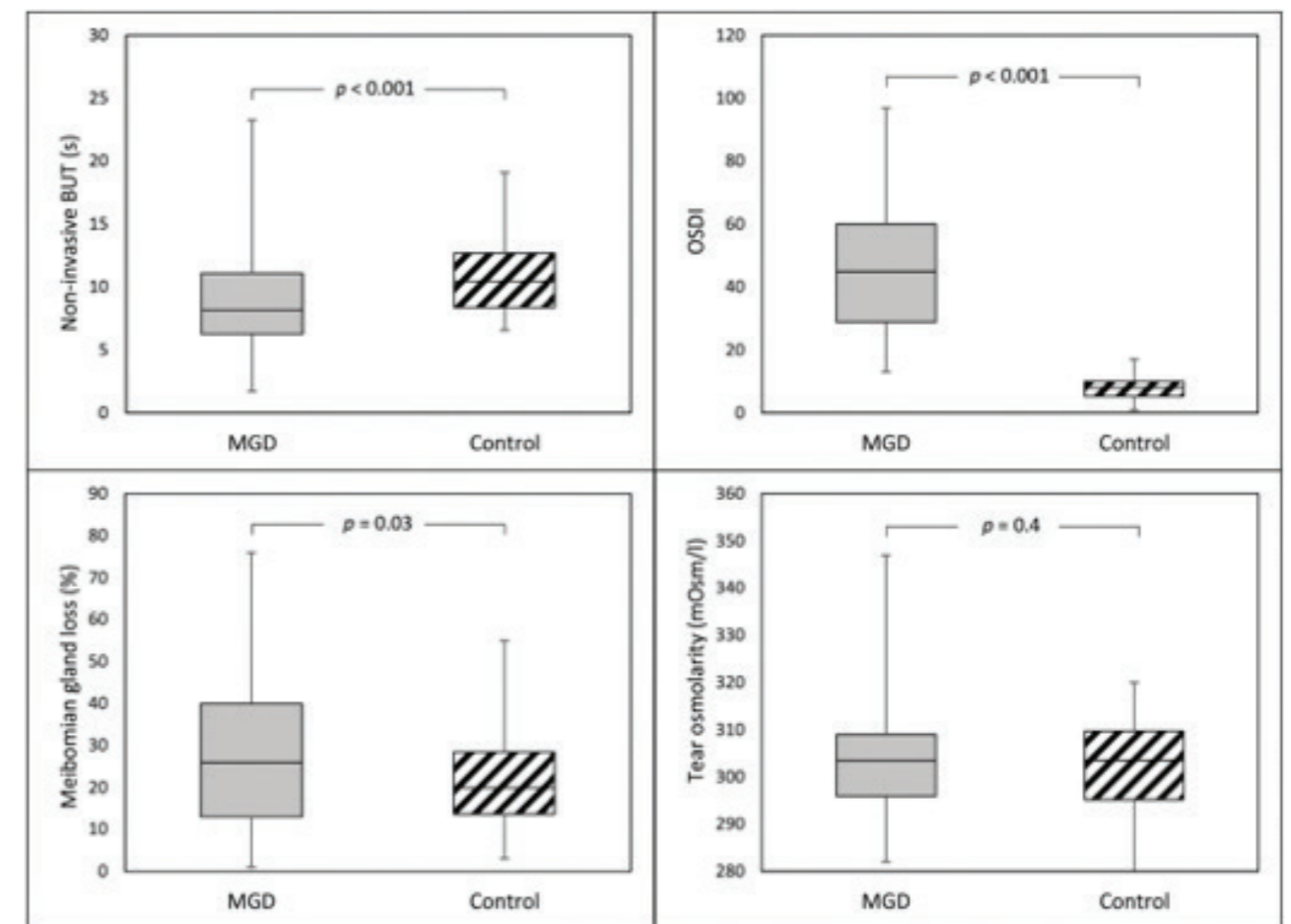


FIGURE 1. Boxplot analysis of non-invasive BUT, ocular surface disease index, meibomian gland loss, and tear osmolarity for both MGD and control groups.

TABLE 1. Correlation Factors Among Variables in the MGD Group

	OSDI	Noninvasive BUT	Meibomian Gland Loss	Lipid Layer Thickness	Tear Osmolarity
OSDI	1	0.100	0.187	0.110	20.103
Noninvasive BUT		1	0.070	0.169	20.057
Meibomian gland loss			1	20.041	0.053
Lipid layer thickness				1	20.083
Tear osmolarity					1

Bold are for P , 0.05.

(grade 5). Meibography was performed by capturing infrared images with the BG-4M noncontact meibography system (SBM Sistemi, Turin, Italy). Images were digitally analyzed using ImageJ software (National Institutes of Health; [http:// imagej.nih.gov/ij](http://imagej.nih.gov/ij)), and meibomian gland loss was defined as the percentage of gland loss in relation to the total tarsal area of the lower eyelid. Tear osmolarity was tested using the TearLab Osmolarity System (TearLab Corporation, San Diego, CA), collecting a 50-nL tear sample from the inferior lateral tear meniscus.⁹

Statistical Analysis

Data analysis was performed using SPSS statistical software (SPSS Inc, Chicago, IL). Values were expressed as mean \pm SD. The Mann-Whitney U test was used to compare OSDI, non-invasive BUT, lipid layer thickness grade, meibomian gland loss, and tear osmolarity between both groups. The correlations among the parameters in the MGD group were calculated using Spearman correlation analysis. Venn diagrams were used to show how the measured parameters might contribute to the diagnosis of MGD. Receiver operating

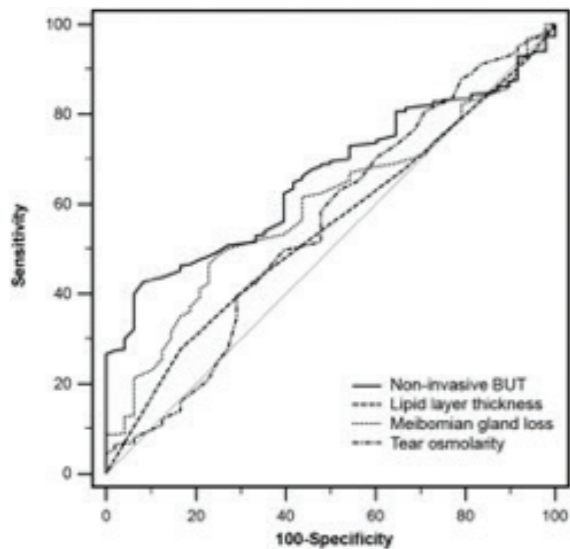


FIGURE 2. ROC curves for non-invasive BUT, meibomian gland

characteristic (ROC) curves with calculations of the area under the curve (AUC) were used to describe the accuracy of each parameter for differentiating patients with MGD from controls. Results were considered statistically significant for P , 0.05.

RESULTS

A total of 352 eyes of 176 patients were included in the study. Of these, 149 patients were affected by MGD (105 women and 44 men; mean age 53.4 \pm 15.5 years), whereas 27 healthy patients acted as a control group (22 women and 5 men; mean age 52.9 \pm 15.2 years). There was no significant difference in the distribution of both age and sex between both groups. The median values and variability of the OSDI, non-invasive BUT, meibomian gland loss, and tear osmolarity in both groups are shown in Figure 1. The mean OSDI was significantly higher in the MGD group than in controls (respectively 37.9 \pm 19.6 vs. 7.1 \pm 2.8; P , 0.001). The non-invasive BUT was significantly shorter in the MGD group than in the control group (8.8 \pm 3.6 vs. 11.0 \pm 3.0; P , 0.001), whereas meibomian gland loss was significantly higher in the MGD group than in the control group (28.0 \pm

17.6 vs. 21.2 \pm 13.0; P = 0.029). There were no significant differences in both lipid layer thickness and tear osmolarity between the MGD group and control group (respectively, 22.2 \pm 1.3 vs. 2.4 \pm 1.5 and 303.5 \pm 6 9.8 vs. 302.7 \pm 6 8.5; always P . 0.05). loss, lipid layer thickness, and tear osmolarity.

TABLE 2. Areas Under the ROC Curves (AUCs) With 95% Confidence Intervals (CIs), Sensitivity, and Specificity for the Calculated Cutoff Values* of Each Parameter

Characteristics	AUC	95% CI	Cutoff	Sensitivity, %	Specificity, %
Noninvasive BUT	0.686	0.635–0.734	#9.6 s	65.8	63.0
Meibomian gland loss	0.598	0.544–0.651	.20%	59.7	61.1
Lipid layer thickness	0.545	0.490–0.599	#2	57.7	33.3
Tear osmolarity	0.555	0.500–0.609	.303 mOsm/L	49.3	53.7

*Determined as the value whose corresponding point on the ROC curve was nearest to the coordinate (0,1).

The correlation analyses among the measured variables in the MGD group are summarized in Table 1. Positive correlations between lipid layer thickness and non-invasive BUT (r = 0.169, P = 0.004) and between meibomian gland loss and OSDI (r = 0.187, P = 0.004) were found.

The ROC curves of non-invasive BUT, lipid layer thickness, meibomian gland loss, and tear osmolarity are shown in Figure 2. The AUC values showed that non-invasive BUT had the highest diagnostic power as a single parameter, followed by meibomian gland loss, tear osmolarity, and lipid layer thickness (Table 2).

A Venn diagram analysis was performed to show how the 4 automated parameters might be able to differentiate patients with MGD from controls (Fig. 3). The cutoff value for each score was determined as the score whose corresponding point on the ROC curve was nearest to the coordinate (0,1). Cutoff values considered abnormal were non-invasive BUT #9.6 seconds, lipid layer thickness grade

#2, meibomian gland loss .20%, and tear osmolarity .303 mOsm/L. Non-invasive BUT showed a sensitivity of 65.8% and a specificity of 63.0%; meibomian gland loss showed a sensitivity of 59.7% and a specificity of 61.1%; the lipid layer thickness grade showed a sensitivity of 57.7% and a specificity of 33.3%; and tear osmolarity showed a sensitivity of 49.3% and a specificity of 53.7%.

The 2 parameters with the highest AUC (namely non-invasive BUT and meibomian gland loss) were combined in parallel, and the diagnostic accuracy was calculated. When the diagnosis of MGD was made based on either non-invasive BUT or meibomian gland loss being abnormal, the sensitivity was 86.2% and the specificity was 38.5%. When the diagnosis was made on both non-invasive BUT and meibomian gland loss being abnormal, the sensitivity was 39.3% and the specificity was 85.6%.

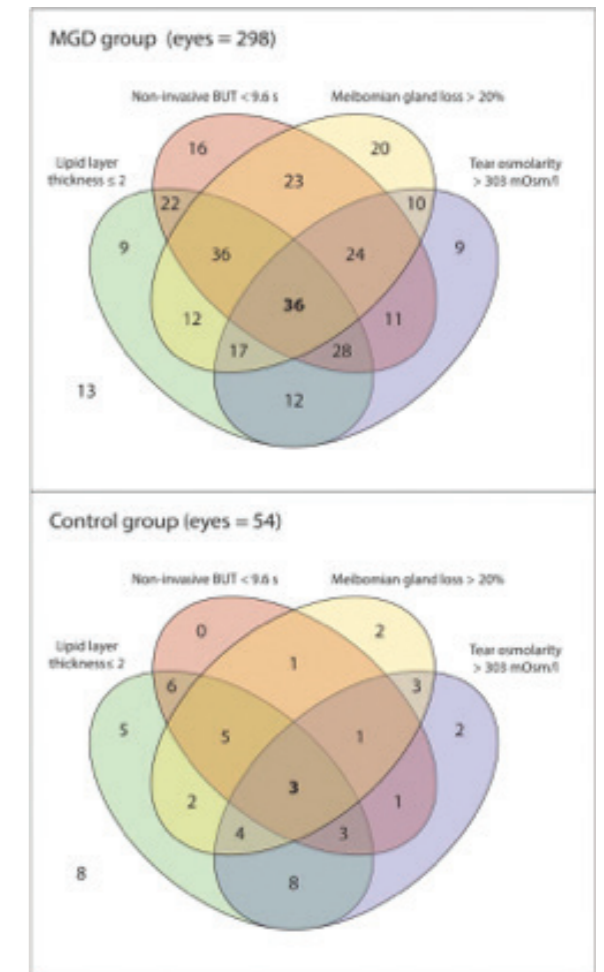


FIGURE 3. Venn diagram analysis of both MGD and control groups. Cutoff values of non-invasive BUT, meibomian gland loss, lipid layer thickness, and tear osmolarity were determined from ROC curves.

DISCUSSION

The accurate diagnosis and classification of dry eye are complicated by the heterogeneous nature of the disease and the variability of signs and symptoms.¹⁰ Various diagnostic assessments have been proposed to qualitatively and quantitatively characterize the entire ocular surface system. However, to date, no universally accepted diagnostic workup for the diagnosis of MGD has been established. Several tests used routinely in daily practice require direct contact with the eye and/or the use of eye drops. The resulting alteration of the tear film volume and composition may not only influence the measured variable itself but also have disruptive effects on the results of subsequent tests. In addition, some tests require the clinician's judgment to reach a score and, therefore, are open to significant observer bias. Furthermore, measurements obtained using traditional tests are often affected by low values of repeatability and reproducibility.¹¹

Recently, new automated non-invasive quantitative tests have been developed to overcome these drawbacks. They include, among others, tear film interferometry, noncontact meibography, and tear osmolarity. In

particular, interferometry is a technique that studies the surface reflection pattern and dynamics of the lipid layer of the tear film, thus allowing the measurement of the tear film stability and the thickness of the lipid layer.¹² The measurement of BUT with a non-invasive technique eliminates the disturbance on the tear film caused by instillation of fluorescein dye.¹³ Meibography allows in vivo observation of the meibomian gland morphology; the gland structural changes may be graded with different scoring systems.^{14,15} In addition, new digital software allows automated calculation of the total meibomian gland area in the lower and upper eyelids.¹⁶ Tear film osmolarity has been reported as the single best metric to diagnose and grade severity of dry eye.¹⁷ However, some authors questioned its clinical utility because of the high variability of measurements and the lack of correlation with dry eye signs and symptoms.¹⁸

In this study, we performed the diagnostic workup using automated non-invasive measurements of various ocular surface parameters in both patients with MGD and healthy controls. Non-invasive BUT was significantly shorter in the MGD group compared with the control group. This result is consistent with previous studies and confirms that MGD reduces the stability of the tear film.^{19,20} The ROC analysis showed that the non-invasive BUT was the parameter with the highest AUC, indicating that it has the highest power to differentiate between MGD and control patients. No association between the non-invasive BUT and OSDI was found, in disagreement with other authors.¹⁸ However, this finding is not surprising because it is well known that ocular surface symptoms have low and inconsistent correlations with clinical signs, including both fluorescein tear and non-invasive BUT.²¹ Meibomian gland loss was shown to be significantly higher in patients with MGD than in controls. Moreover, a significant correlation between meibomian gland loss and OSDI was found, in accordance with previous studies.^{10,20,22} The ROC analysis indicated that the meibomian gland loss score was the second best parameter to differentiate patients with MGD from the normal population. Its high diagnostic accuracy and positive correlations with lid margin abnormalities and meibum quality and expressibility were previously demonstrated.¹⁹

Lipid layer thickness showed a significant correlation with non-invasive BUT but did not significantly differ between patients with MGD and controls. It should be also noted that lipid layer thickness showed inconsistent correlations with TBUT, ocular symptoms, and meibomian gland loss across different studies.^{10,23–26} This finding may be related to several confounding factors potentially influencing its measure, such as the use of lipid-containing eye drops, the palpebral aperture, and the gaze position.²⁶

Tear osmolarity did not significantly differ between patients with MGD and controls. Furthermore, it did not show any correlation with the other measured parameters. It was previously hypothesized that tear osmolarity may not be increased in patients with MGD because the disease alone may not be sufficient at overwhelming the homeostatic control in many patients.²⁷ However, previous studies showed that there was increased variability attributable to errors in repeated measurements in both patients with dry eye and those with MGD compared with control participants, thus making the clinical interpretation of its measurements unclear.^{18,28}

In this study, the non-invasive BUT and meibomian gland loss resulted in the tests with the highest diagnostic power; by combining the 2 tests in parallel, MGD may be strongly suspected when 1 of these 2 tests is abnormal. However, it should be highlighted that these values are lower compared with the other traditional tests: for instance, Arita et al¹⁹ reached the diagnosis with a sensitivity of 84.9% and a specificity of 96.7% using the combination of meibomian gland loss, lid margin abnormalities, and ocular symptoms. However, our automated ocular surface workup has several potential advantages: the techniques are non-invasive, not altering the volume or the properties of the tear film, and the results of subsequent tests; they are examiner independent and may be easily performed as a screening tool by trained nonophthalmologist medical personnel, and they are more objective than clinician-derived estimates, thus minimizing the risk of observer bias. In addition, the diagnostic power of the proposed workup could be further improved in clinical practice by incorporating the OSDI score, which is also a non-invasive measure that can be administered by nonophthalmologists.

In conclusion, the automated non-invasive ocular surface diagnostic workup used in this study may represent a promising diagnostic tool for MGD diagnosis. Although no single test has proved able to reach the diagnosis with sufficient accuracy, MGD may be strongly suspected when one between non-invasive BUT and meibography combined in parallel is abnormal. In case of positivity of either non-invasive BUT or meibomian gland loss, subsequent qualitative clinical tests should be performed to achieve a reliable diagnosis and more precise characterization of MGD.

BIBLIOGRAPHY

REFERENCES

- Craig JP, Nichols KK, Akpek EK, et al. TFOS DEWS II definition and classification report. *Ocul Surf*. 2017;15:276–283.
- Miljanović B, Dana R, Sullivan DA, et al. Impact of dry eye syndrome on vision-related quality of life. *Am J Ophthalmol*. 2007;143:409–415.
- Nichols KK, Foulks GN, Bron AJ, et al. The international workshop on meibomian gland dysfunction: executive summary. *Invest Ophthalmol Vis Sci*. 2011;52:1922–1929.
- Nelson JD, Shimazaki J, Benitez-del-Castillo JM, et al. The international workshop on meibomian gland dysfunction: report of the definition and classification subcommittee. *Invest Ophthalmol Vis Sci*. 2011;52:1930–1937.
- Knop E, Knop N, Millar T, et al. The International Workshop on Meibomian Gland Dysfunction: report of the subcommittee on anatomy, physiology, and pathophysiology of the meibomian gland. *Invest Ophthalmol Vis Sci*. 2011;52:1938–1978.
- Baudouin C, Messmer EM, Aragona P, et al. Revisiting the vicious circle of dry eye disease: a focus on the pathophysiology of meibomian gland dysfunction. *Br J Ophthalmol*. 2016;100:300–306.
- Tomlinson A, Bron AJ, Korb DR, et al. The international workshop on meibomian gland dysfunction: report of the diagnosis subcommittee. *Invest Ophthalmol Vis Sci*. 2011;52:2006–2049.
- Roy NS, Wei Y, Kuklinski E, et al. The growing need for validated biomarkers and endpoints for dry eye clinical research. *Invest Ophthalmol Vis Sci*. 2017;58:BI01–BI019.
- Versura P, Profazio V, Giannaccare G, et al. Discomfort symptoms reduction and ocular surface parameters recovery with Artelac Rebalance treatment in mild-moderate dry eye. *Eur J Ophthalmol*. 2013;23:488–495.
- Ji YW, Lee J, Lee H, et al. Automated measurement of tear film dynamics and lipid layer thickness for assessment of non-Sjögren dry eye syndrome with meibomian gland dysfunction. *Cornea*. 2017;36:176–182.
- Nichols KK, Mitchell GL, Zadnik K. The repeatability of clinical measurements of dry eye. *Cornea*. 2004;23:272–285.
- Guillon M, Styles E, Guillon JP, et al. Preocular tear film characteristics of nonwearers and soft contact lens wearers. *Optom Vis Sci*. 1997;74: 273–279.
- Nichols JJ, Nichols KK, Puente B, et al. Evaluation of tear film interference patterns and measures of tear break-up time. *Optom Vis Sci*. 2002;79:363–369.
- Arita R, Itoh K, Inoue K, et al. Noncontact infrared meibography to document age-related changes of the meibomian glands in a normal population. *Ophthalmology*. 2008;115:911–915.
- Nichols JJ, Berntsen DA, Mitchell GL, et al. An assessment of grading scales for meibography images. *Cornea*. 2005;24:382–388.
- Ban Y, Shimazaki-Den S, Tsubota K, et al. Morphological evaluation of meibomian glands using noncontact infrared meibography. *Ocul Surf*. 2013;11:47–53.
- Versura P, Profazio V, Campos EC. Performance of tear osmolarity compared to previous diagnostic tests for dry eye diseases. *Curr Eye Res*. 2010;35:553–564.
- Messmer EM, Bulgen M, Kampik A. Hyperosmolarity of the tear film in dry eye syndrome. *Dev Ophthalmol*. 2010;45:129–138.
- Arita R, Itoh K, Maeda S, et al. Proposed diagnostic criteria for obstructive meibomian gland dysfunction. *Ophthalmology*. 2009;116:2058–2063.
- Qi Y, Zhang C, Zhao S, et al. A novel non-invasive ocular surface analyzer for the assessment of dry eye with Meibomian gland dysfunction. *Exp Ther Med*. 2017;13:2983–2988.
- Bartlett JD, Keith MS, Sudharshan L, et al. Associations between signs and symptoms of dry eye disease: a systematic review. *Clin Ophthalmol*. 2015;9:1719–1730.
- Pult H, Riede-Pult BH. Non-contact meibography: keep it simple but effective. *Cont Lens Anterior Eye*. 2012;35:77–80.
- Eom Y, Lee JS, Kang SY, et al. Correlation between quantitative measurements of tear film lipid layer thickness and meibomian gland loss in patients with obstructive meibomian gland dysfunction and normal controls. *Am J Ophthalmol*. 2013;155:1104–1110.
- Isreb MA, Greiner JV, Korb DR, et al. Correlation of lipid layer thickness measurements with fluorescein tear film break-up time and Schirmer's test. *Eye*. 2003;17:79–83.
- Blackie CA, Solomon JD, Scaffidi RC, et al. The relationship between dry eye symptoms and lipid layer thickness. *Cornea*. 2009;28:789–794.
- Finis D, Pischel N, Schrader S, et al. Evaluation of lipid layer thickness measurement of the tear film as a diagnostic tool for Meibomian gland dysfunction. *Cornea*. 2013;32:1549–1553.
- Potvin R, Makari S, Rapuano CJ. Tear film osmolarity and dry eye disease: a review of the literature. *Clin Ophthalmol*. 2015;9:2039–2047.
- Bunya VY, Fuerst NM, Pistilli M, et al. Variability of tear osmolarity in patients with dry eye. *JAMA Ophthalmol*. 2015;133:662–667.

ACKNOWLEDGMENTS

This report would not have been possible without the assistance of doctors and hospitals that provided data and shared worldwide their knowledge and experience on the current situation regarding Dry Eye Disease.

The ATLAS project is implemented under the overall direction of Doctor Luca Vigo.

The principal writing of this report was done by the SBM Sistemi Staff.

Other main contributors included Natasha Pahuja, Luca Vigo, Shri Ganesh, Franco Spedale, Francesco Blasetti, Eros Radrizzani.

Data collation, compilation and statistical data analyses were carried out by SBM Sistemi Distributors in their respective countries.

The data collection from countries and the production of this report would not have been possible without the collaboration of the regional distributor who also provided valuable contributions at different stages of the development of the book.

Mr. Anil Kai from Vision Progress Bangalore, Gabriele Lepri from Monza, Azzarita Giovanni from Cagliari.



www.sbmsistemi.com

Strada Torino, 43 - 10043 Orbassano (Torino) Italy
Tel. +39.011.19923378 - info@sbmsistemi.com